Cysts of the jaw

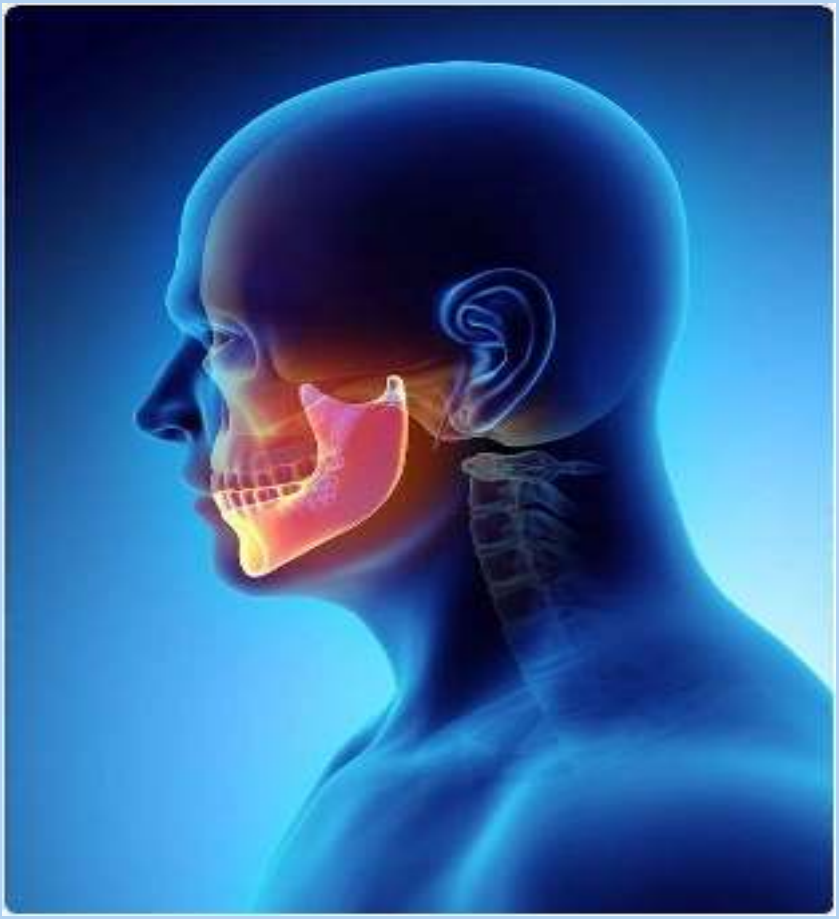

What is a jaw cyst?

- **Cysts are epithelium-lined pathological cavities, usually filled with fluid, semi-solid material, or cellular debris.**

- **‘a pathological cavity having fluid or semi-fluid contents that has not been created by the accumulation of pus’**

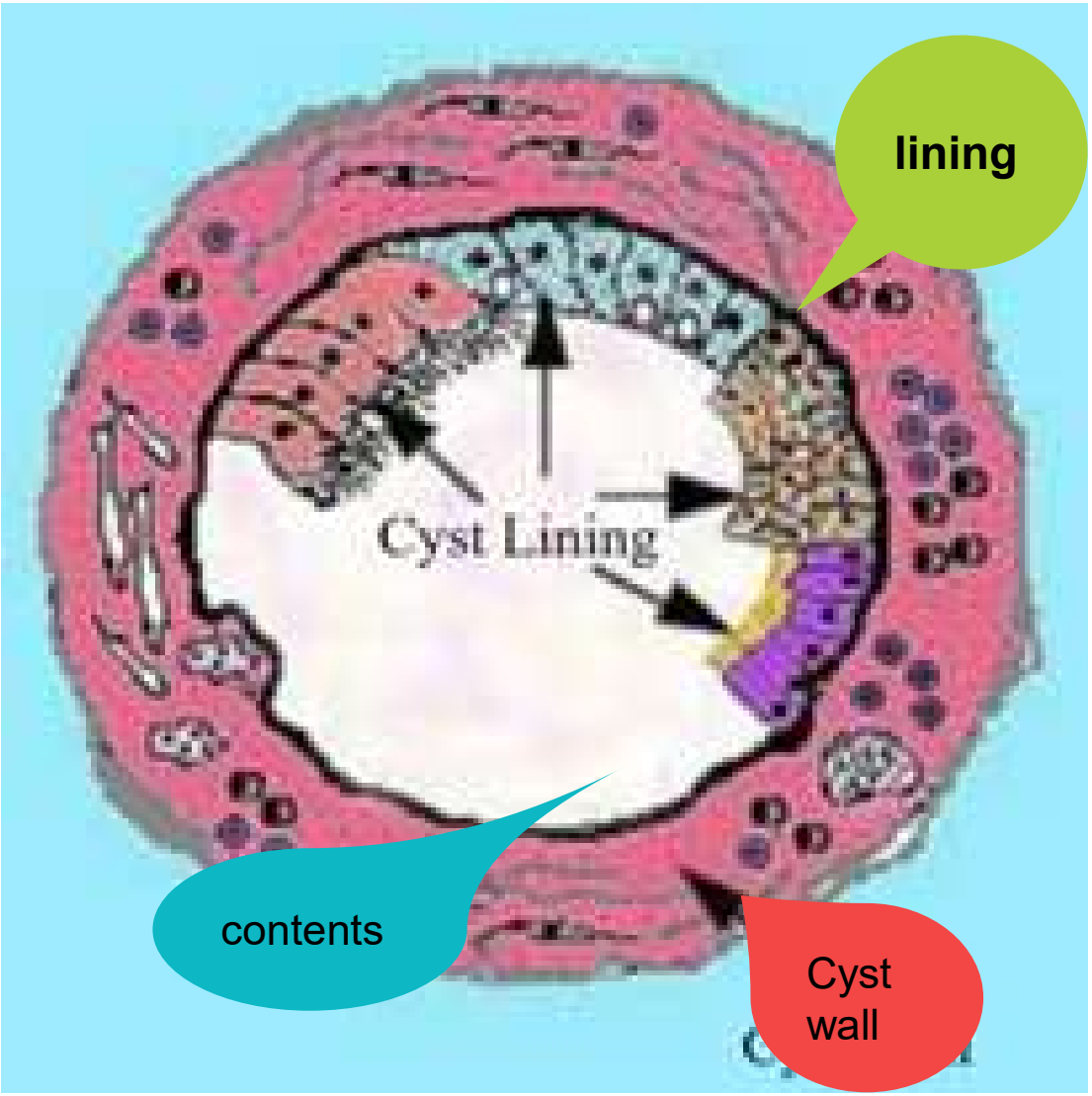

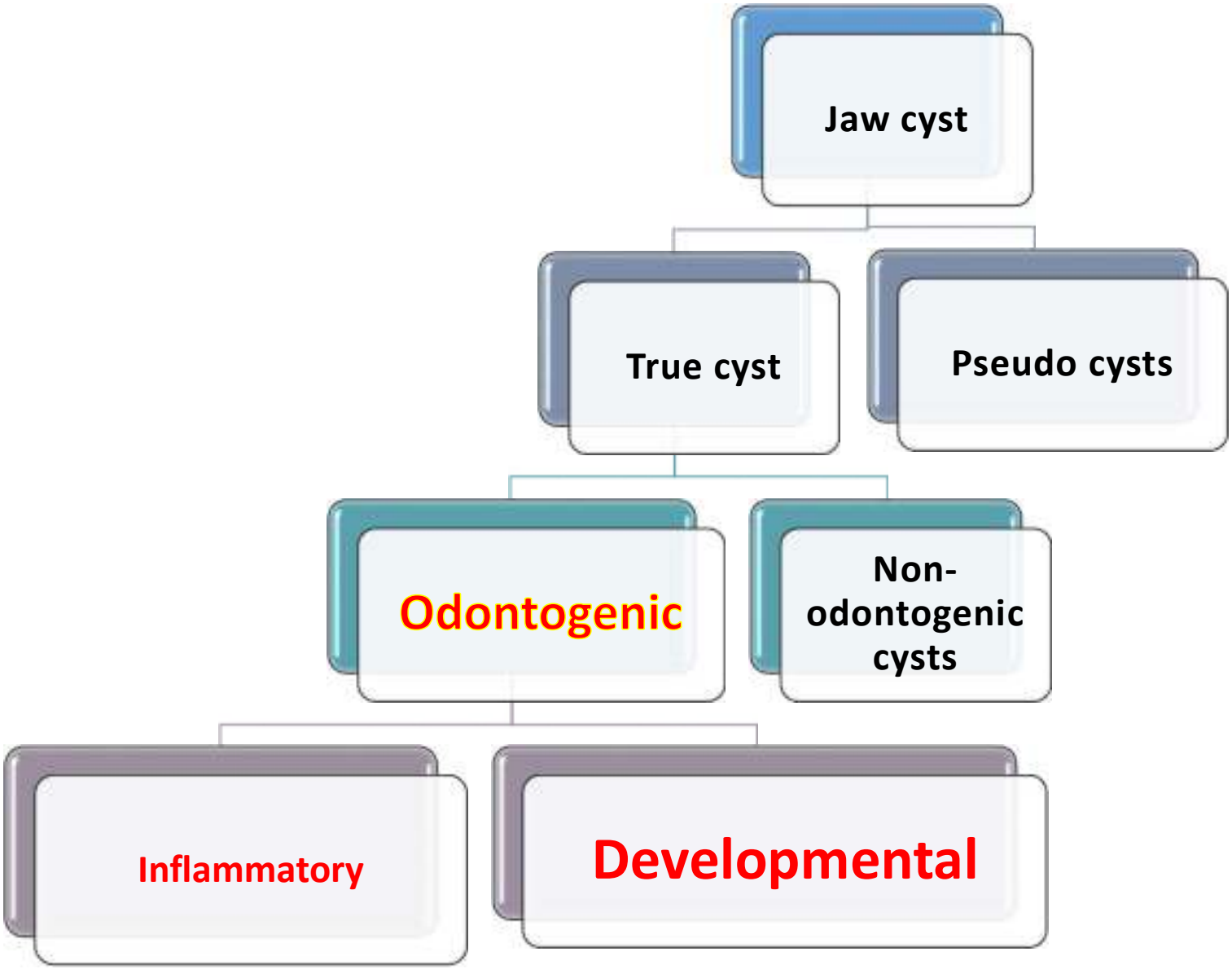
Jaw cyst
True cyst
Pseudo cysts
Odontogenic
Non-odontogenic cysts
Inflammatory
Developmental

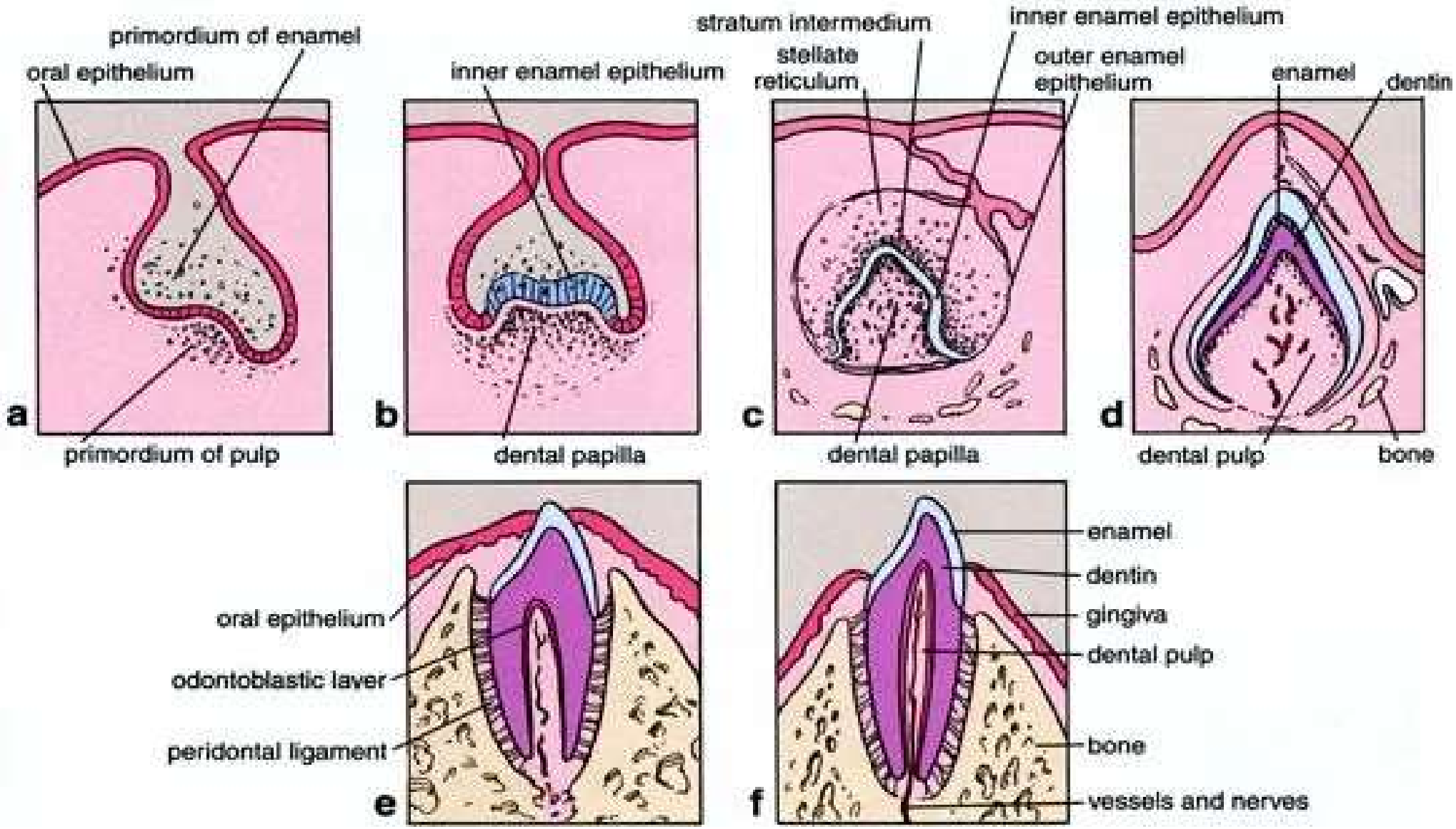
a
primordium of enamel
oral epithelium
primordium of pulp
b
inner enamel epithelium
dental papilla
c
stratum intermedium
inner enamel epithelium
stellate reticulum
outer enamel epithelium
dental papilla
d
enamel
dentin
dental pulp
bone
e
oral epithelium
odontoblastic layer
peridontal ligament
f
enamel
dentin
gingiva
dental pulp
bone
vessels and nerves

II-Odontogenic cysts

a-developmental

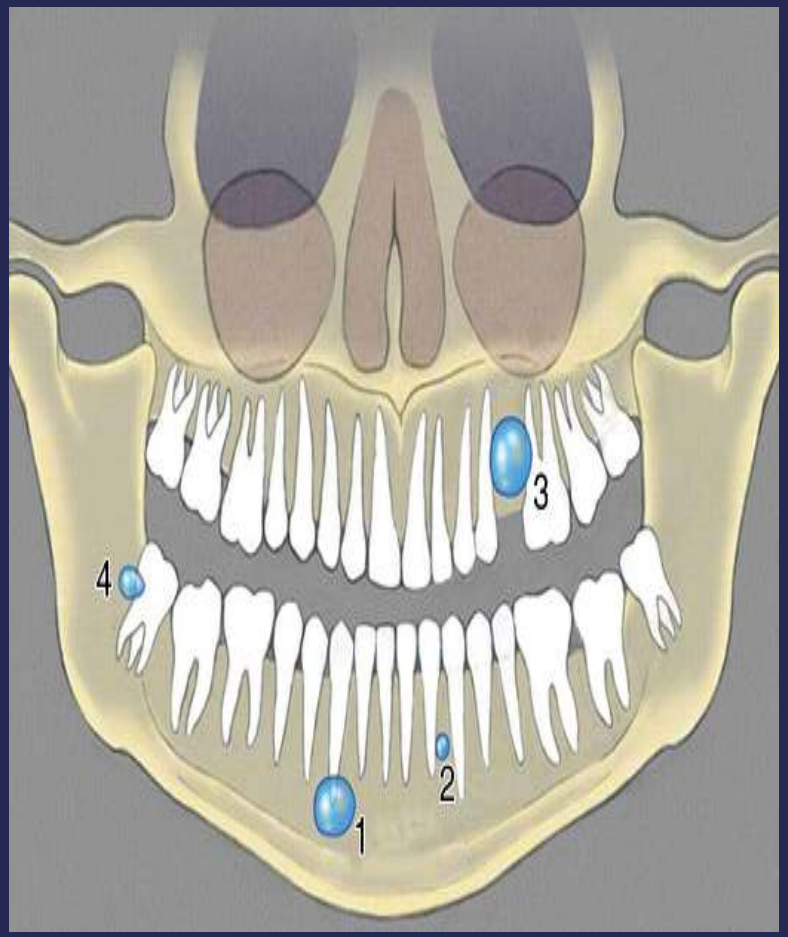

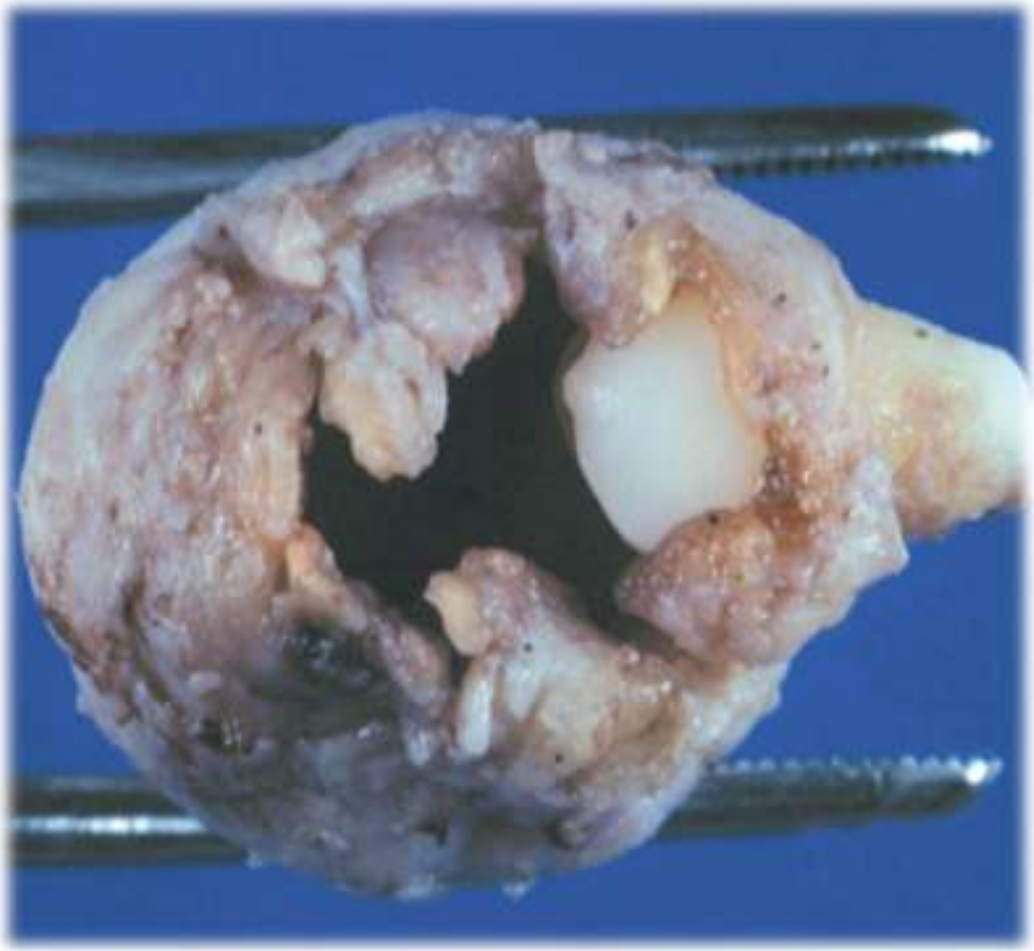

Dentigerous Cyst.

Gross specimens of a dentigerous cysts involving unerupted teeth.

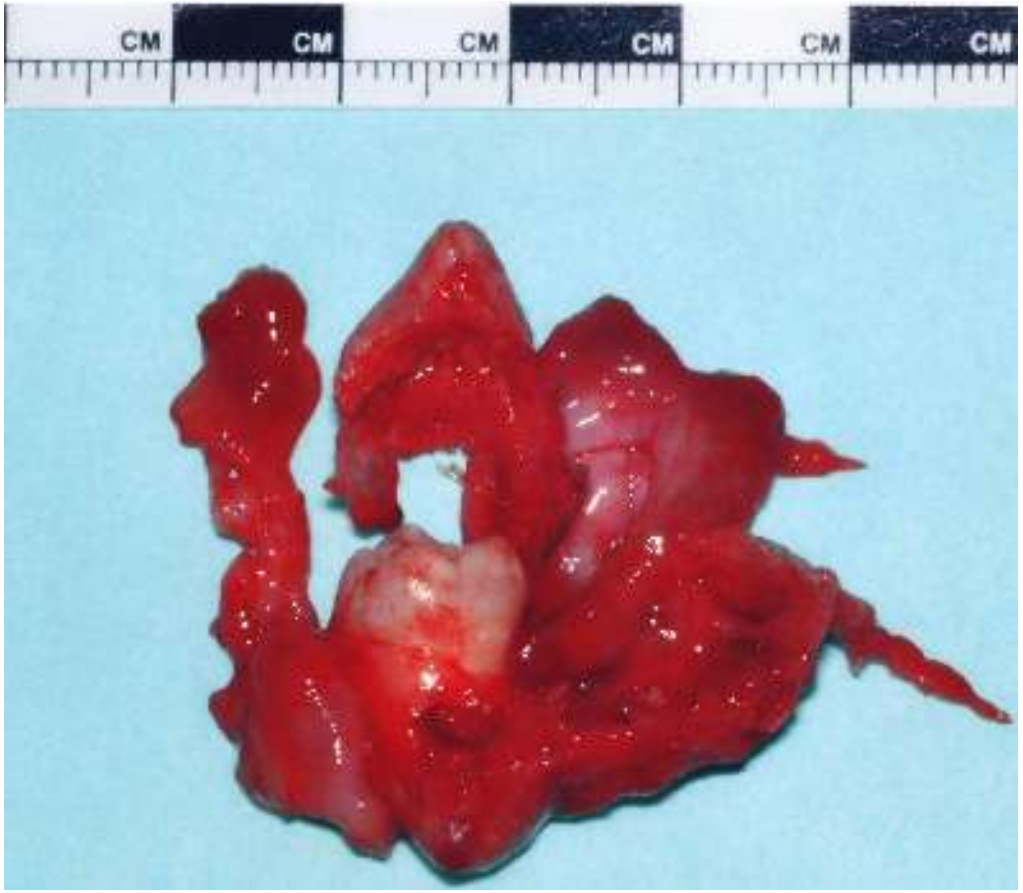

Dentigerous cyst showing the relationship of the cyst to the crown of the tooth.

Pathogenesis

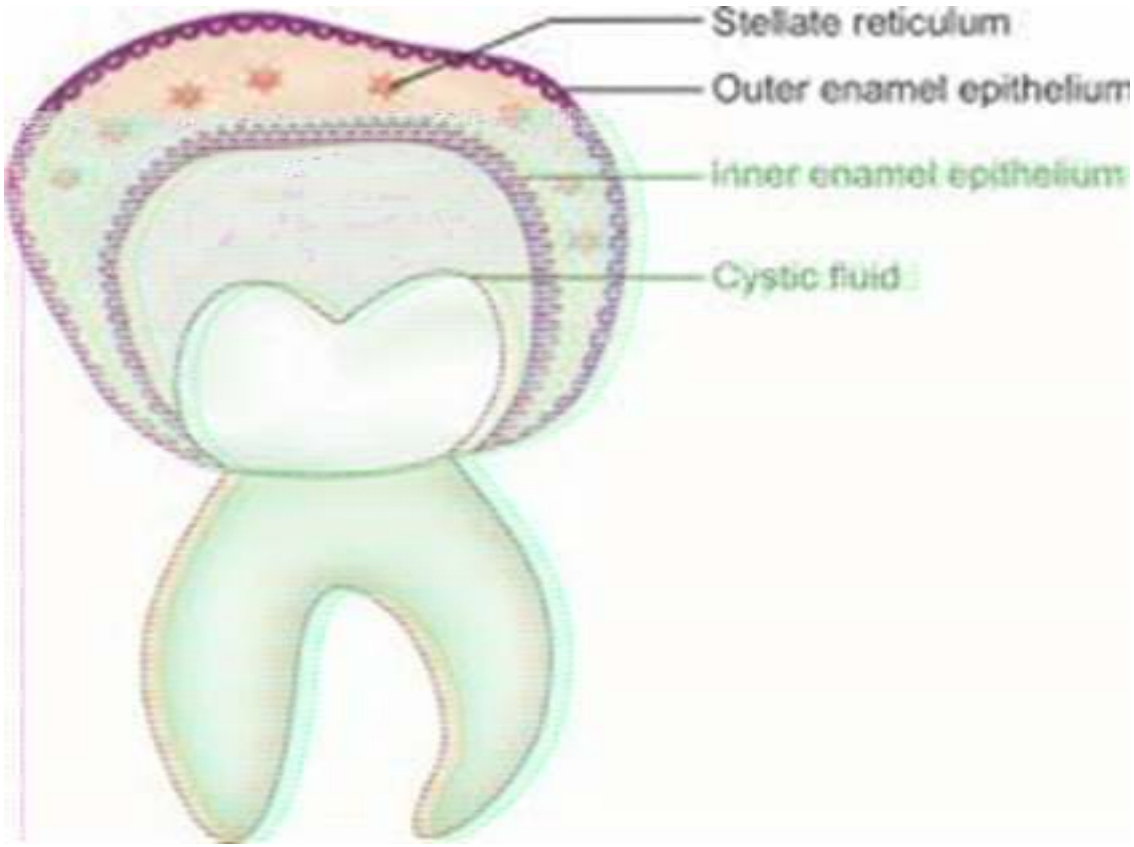

Dentigerous cyst

OPG: A unilocular well-defined radiolucent lesion surrounding impacted mandibular molars.

Dentigerous cyst associated with a right mandibular third molar (Cone beam CT).

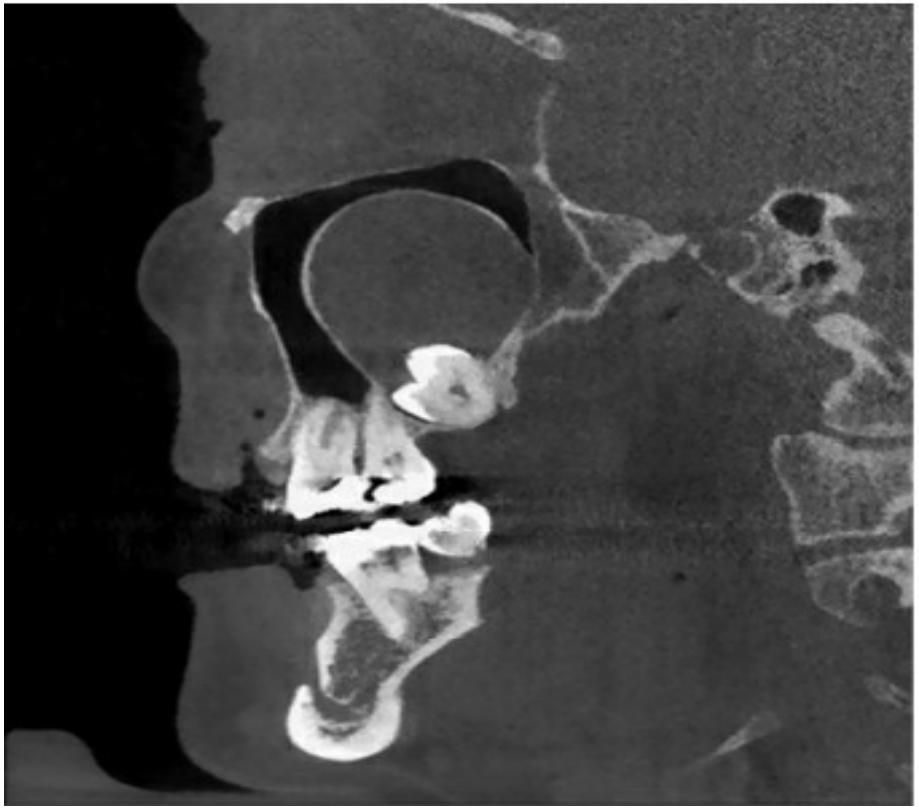

Dentigerous cyst associated with a maxillary third molar (Cone beam CT).

Radiographical variants of D.C.

Central type the crown projecting into the cystic cavity.

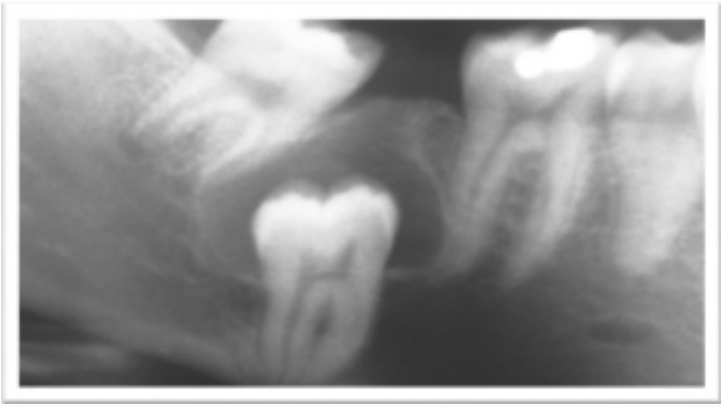

Lateral type: a large cyst along the mesial root of the unerupted molar. This cyst exhibited mucous cell prosoplasia.

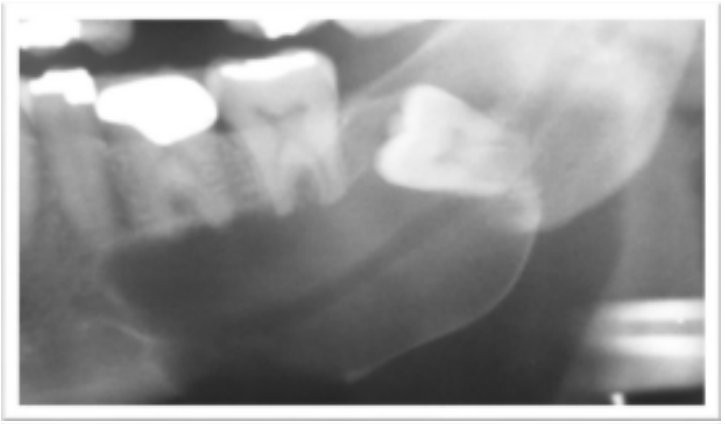

Circumferential type: cyst extension along the mesial and distal roots of the unerupted tooth.

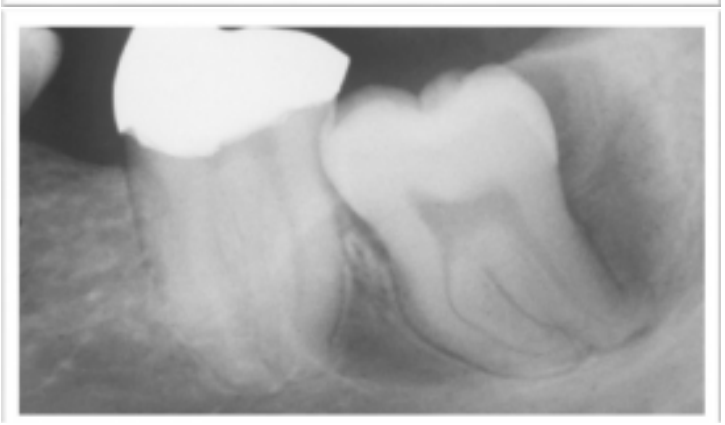

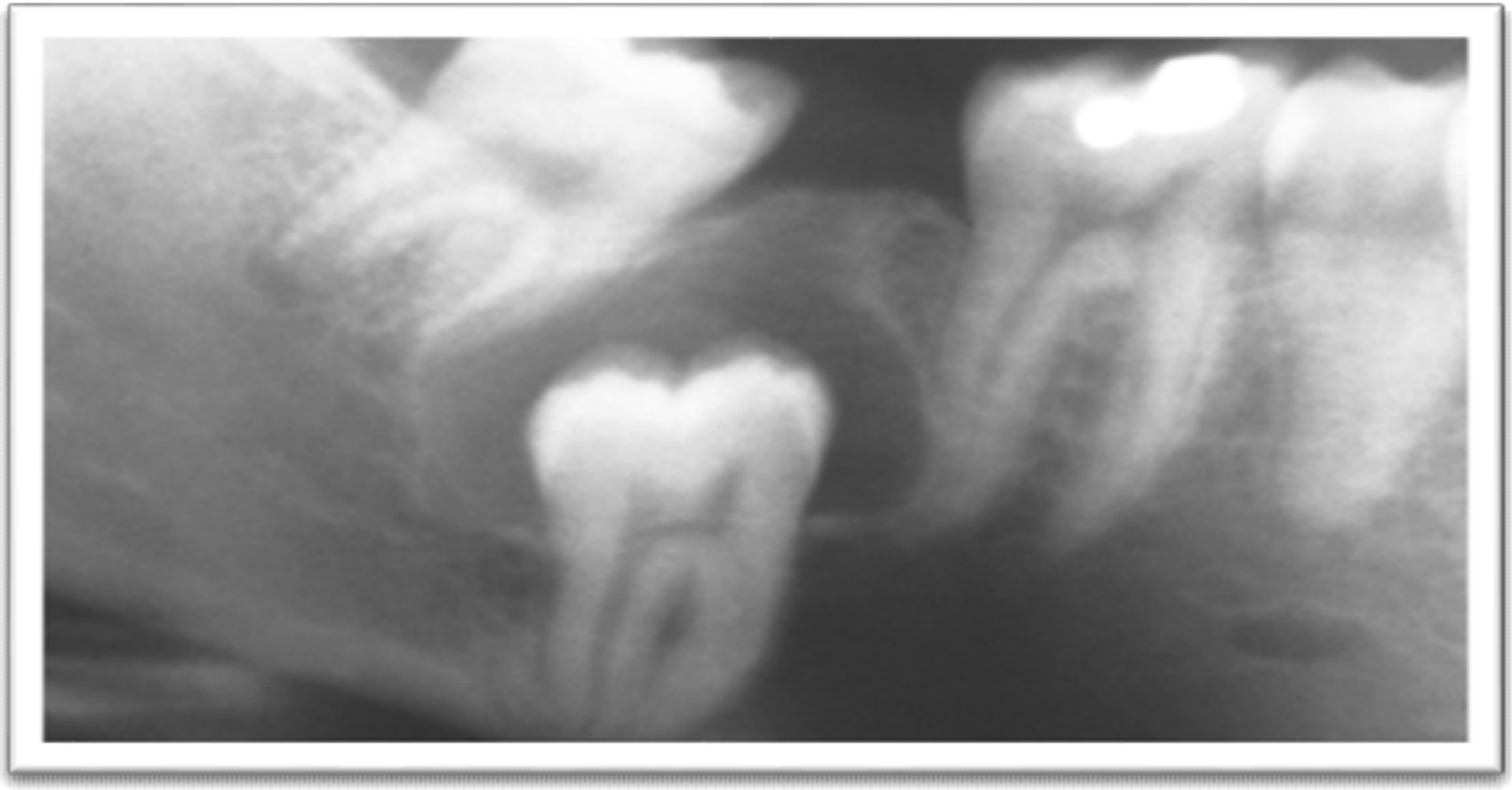

***Dentigerous Cyst*. Central type showing the crown projecting into the cystic cavity.**

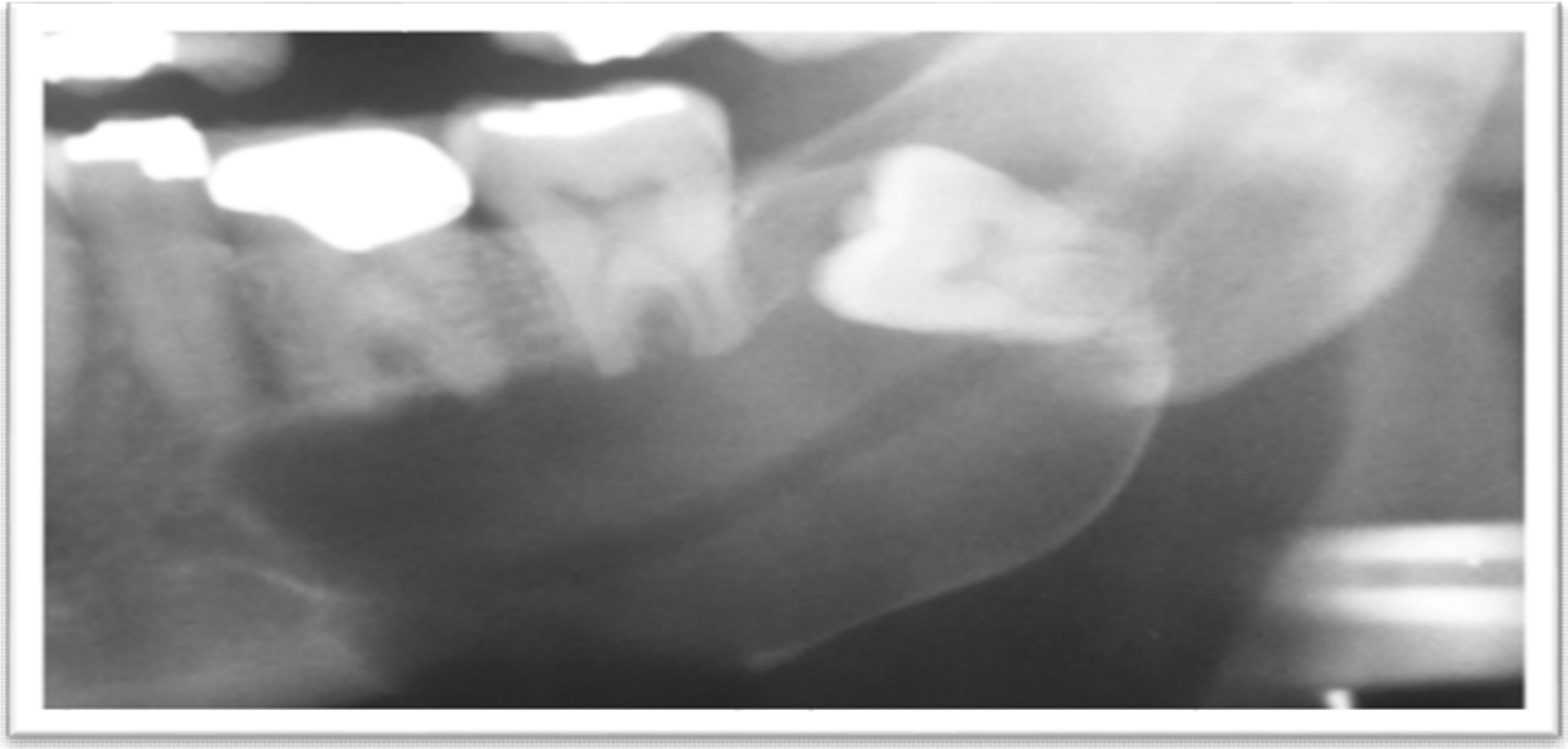

***Dentigerous Cyst*. Lateral variety showing a large cyst along the mesial root of the unerupted molar. This cyst exhibited mucous cell prosoplasia.**

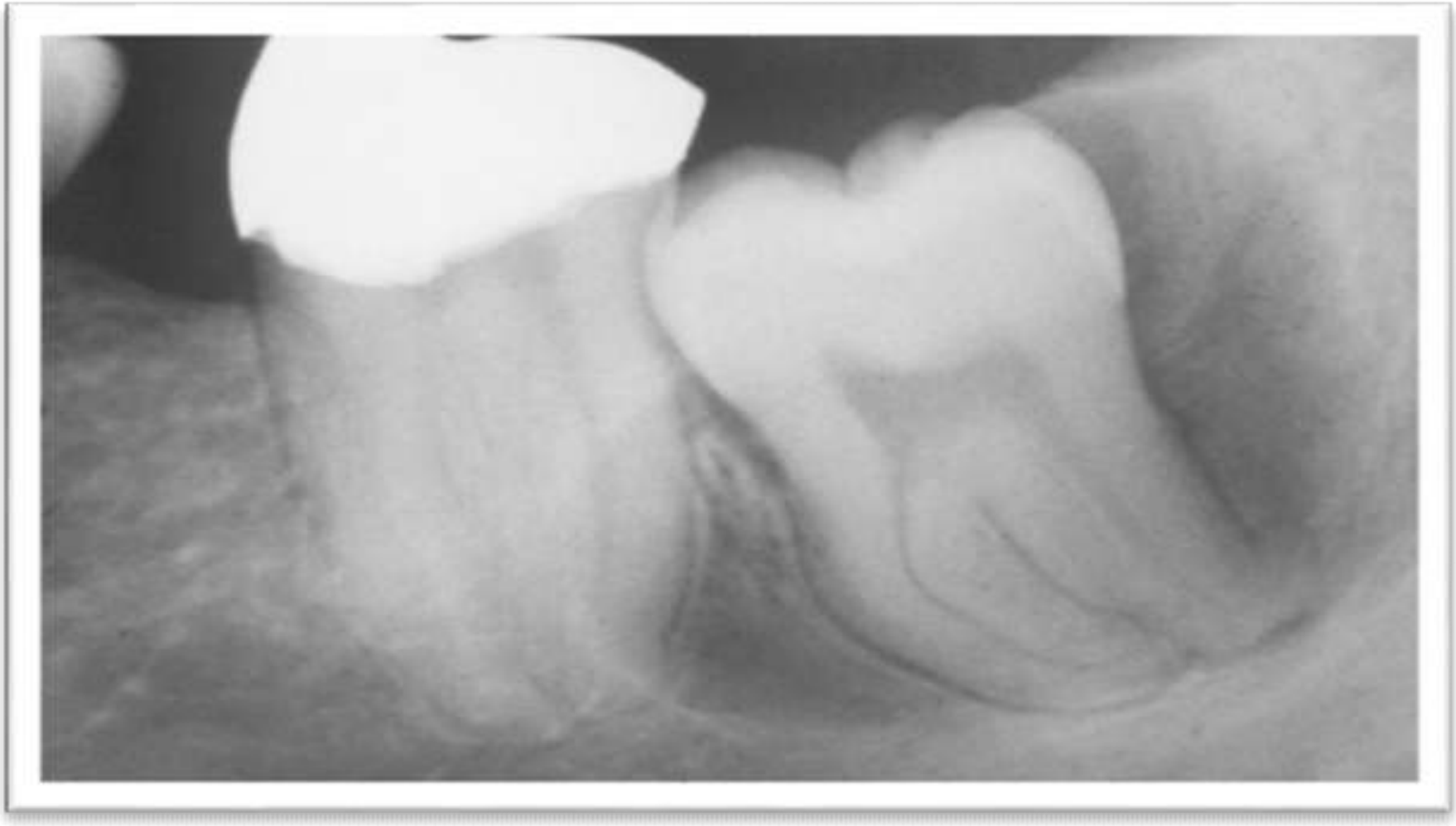

***Dentigerous Cyst*. Circumferential variety showing cyst extension along the mesial and distal roots of the unerupted tooth**.

Dentigerous Cyst or Enlarged Follicle. Radiolucent lesion involving the crown of an unerupted mandibular premolar. Distinction between a dentigerous cyst and an enlarged follicle for a lesion of this size by radiographic and even histopathologic means is difficult, if not impossible.

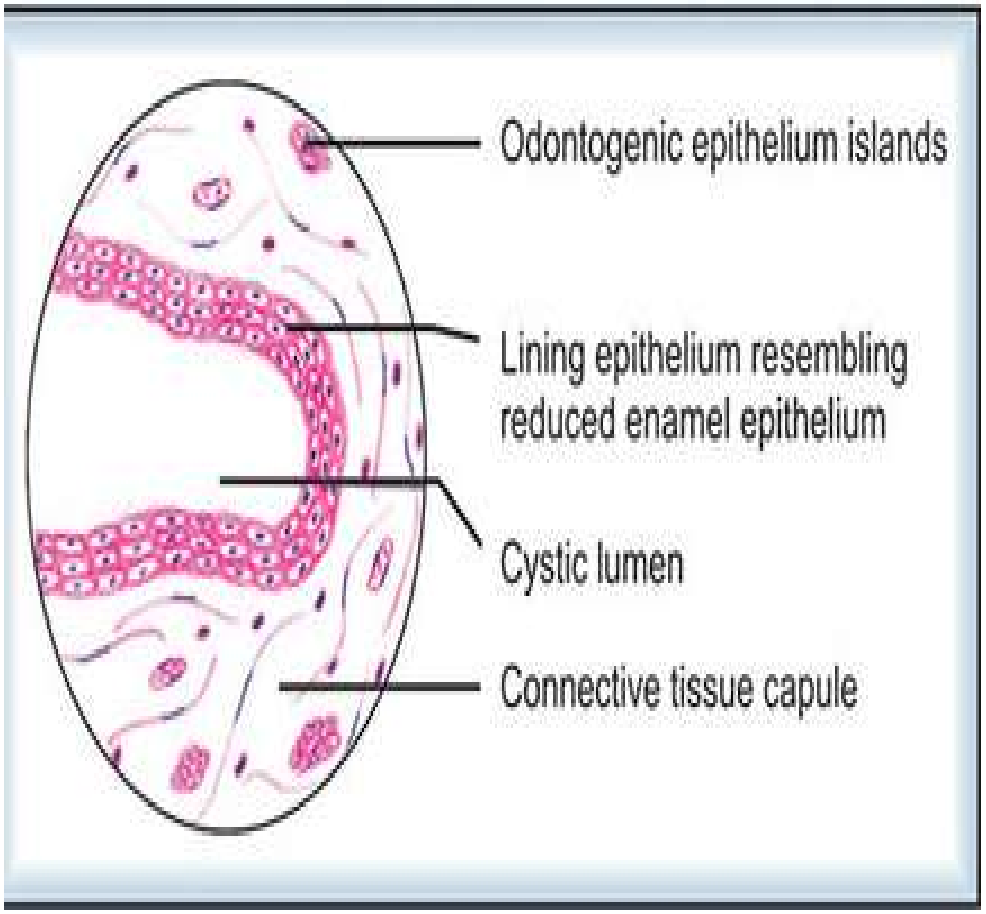

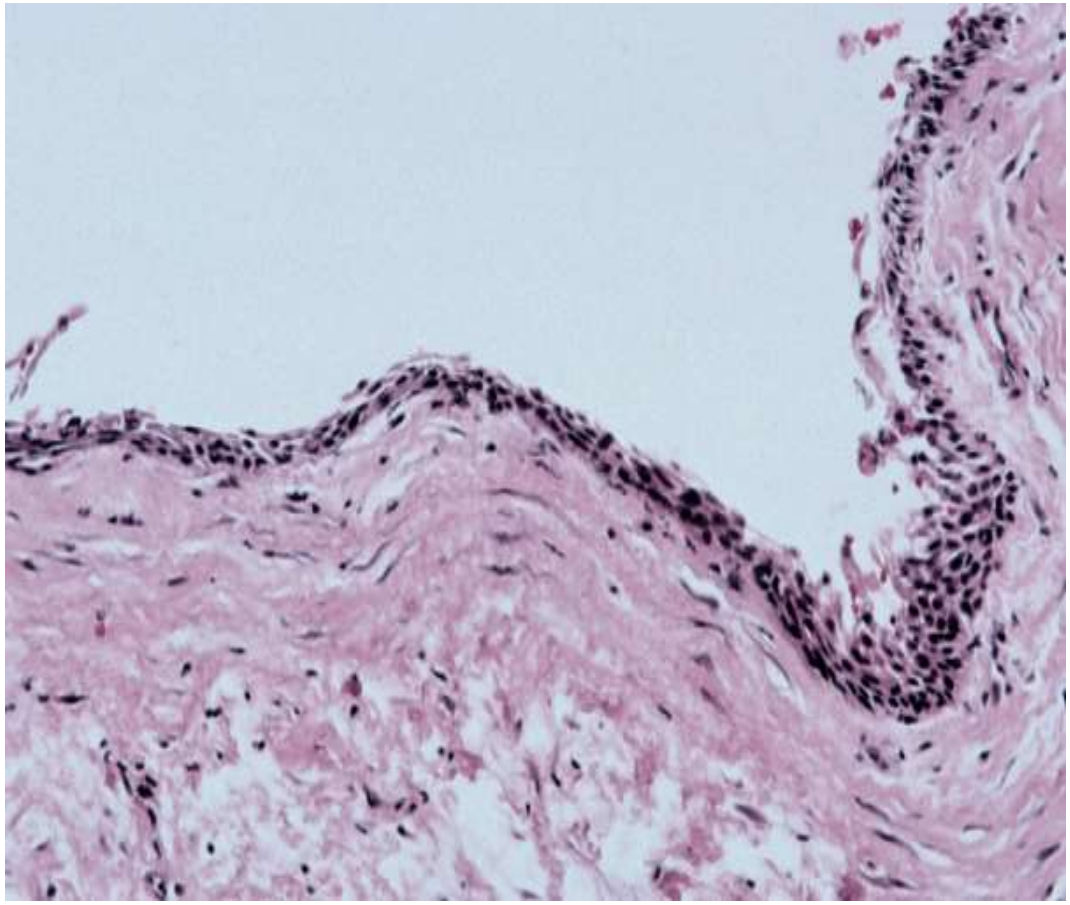

***Dentigerous Cyst*. This non-inflamed dentigerous cyst shows a thin, nonkeratinized epithelial lining.**

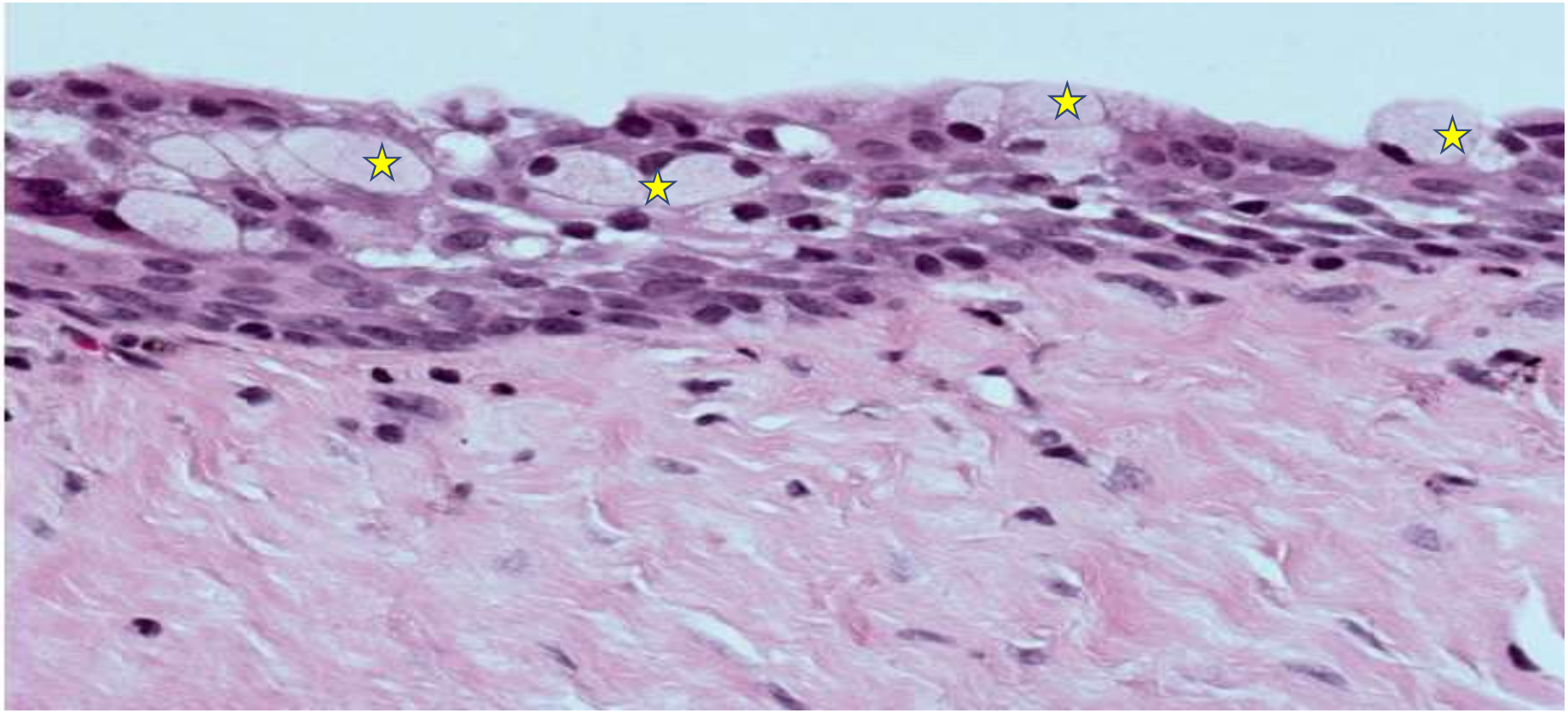

***Dentigerous Cyst*. Scattered mucous cells(star) can be seen within the epithelial lining.**

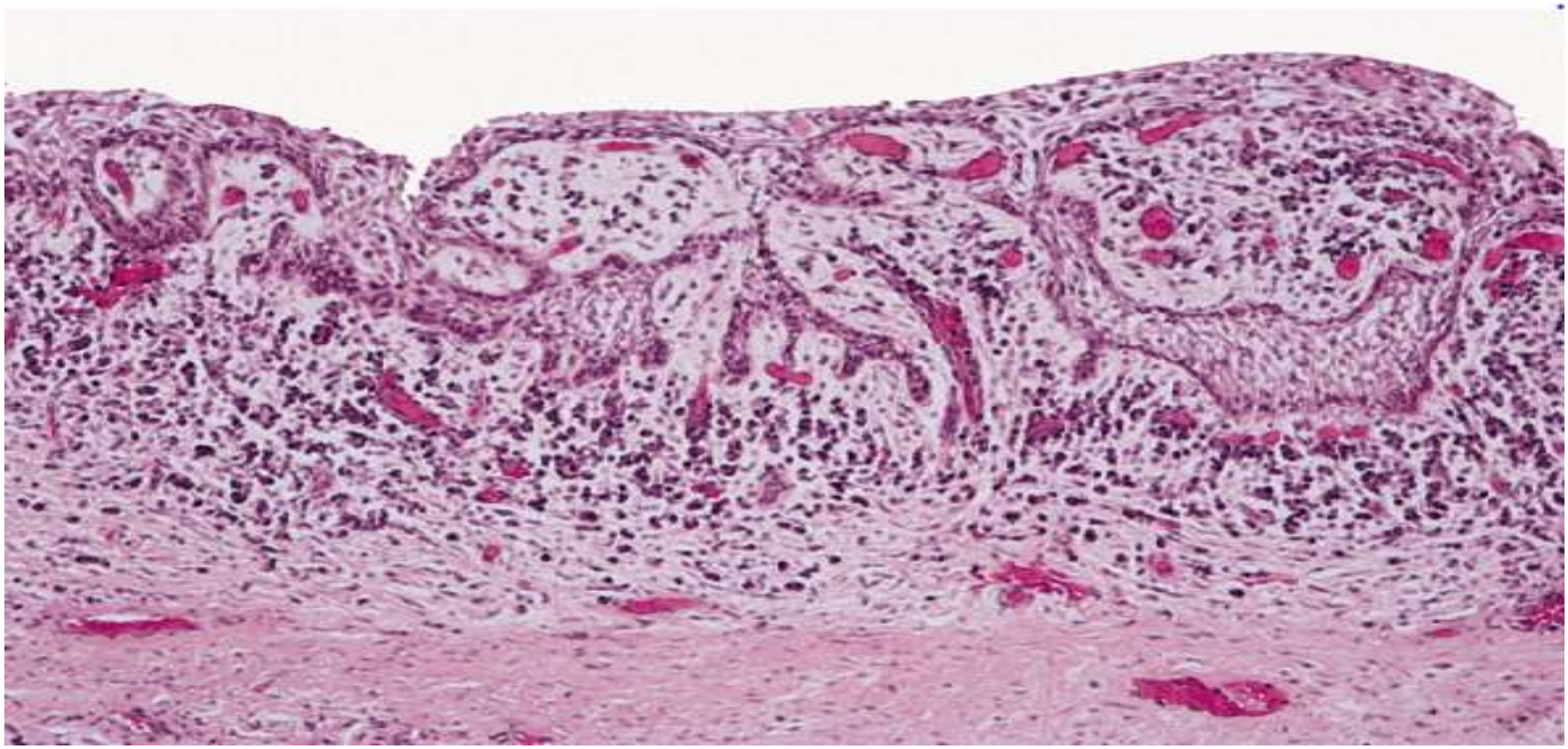

***Dentigerous Cyst*. This inflamed dentigerous cyst shows a thicker epithelial lining with hyperplastic rete ridges. The fibrous cyst capsule shows a diffuse chronic inflammatory infiltrate.**

***Eruption Cyst*. This soft gingival swelling contains considerable blood and can also be designated as an eruption hematoma**

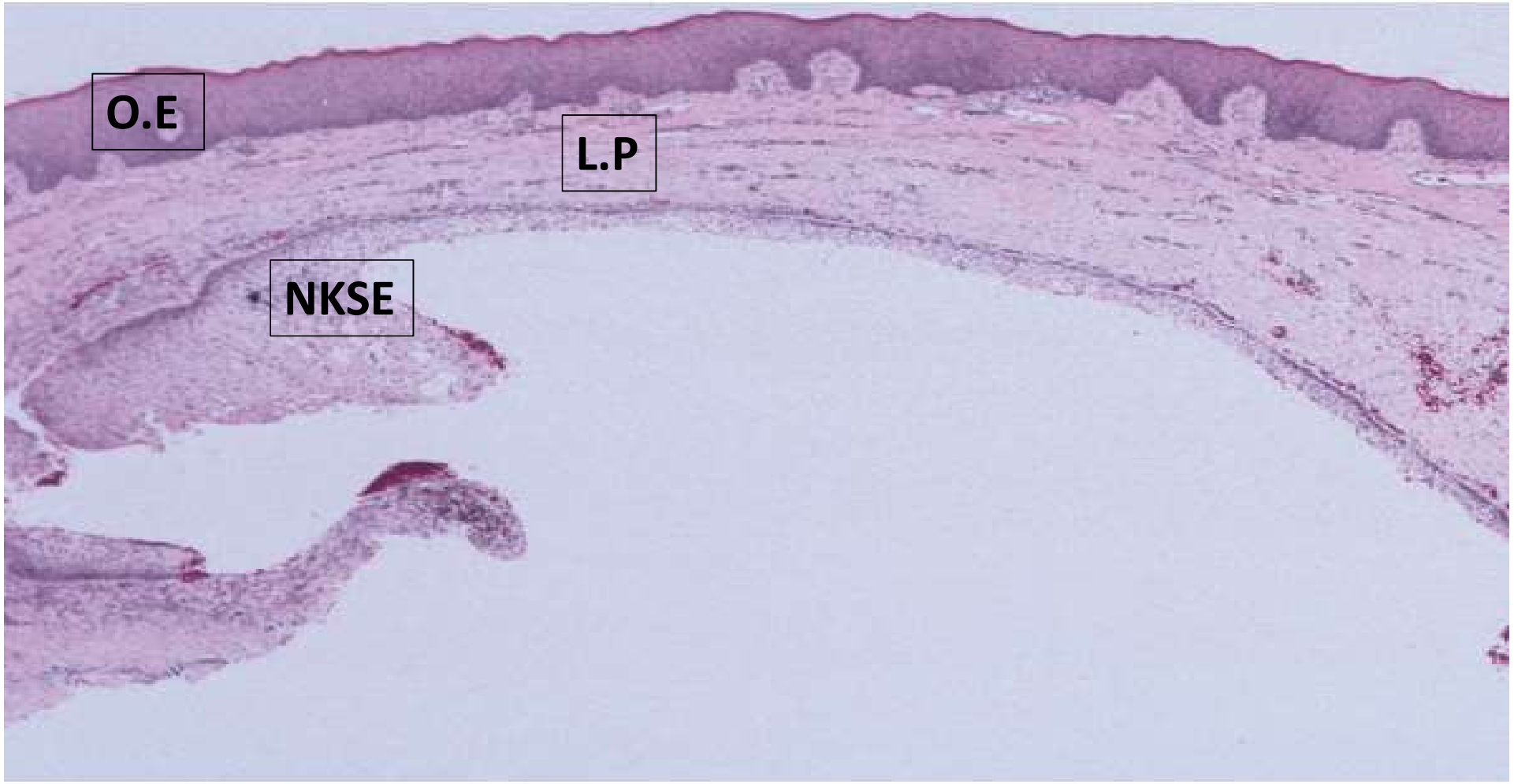

***Eruption Cyst*. A cystic epithelial cavity can be seen below the mucosal surface**.

***Gingival Cyst of the Newborn*. Multiple whitish papules on the alveolar ridge of a newborn infant.**

***Gingival Cyst of the Newborn*. Multiple whitish papules on the alveolar ridge of a newborn infant.**

Odontogenic keratocyst(OKC)

- OKCs found in patients range from infancy to old age, but 60% of cases in 10- 40 years of age. There is a slight male predilection.

- The mandible is involved in 60% to 80% of cases, with a marked tendency to involve the posterior body and ramus.

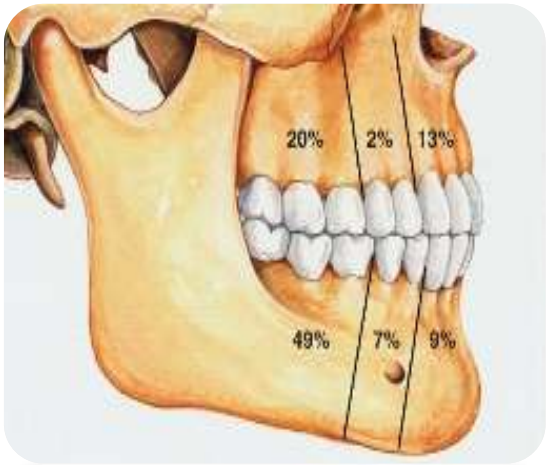

- Small OKCs are usually asymptomatic and discovered only during the course of a radiographic examination.
- Larger OKCs may be associated with pain, swelling, or drainage. Some extremely large cysts, however, may cause no symptoms

- ***OKCs tend to grow in an anteroposterior direction within the medullary cavity of the bone without causing obvious bone expansion.***

This feature may be useful in differential clinical and radiographic diagnosis because dentigerous and radicular cysts of comparable size are usually associated with bony expansion.

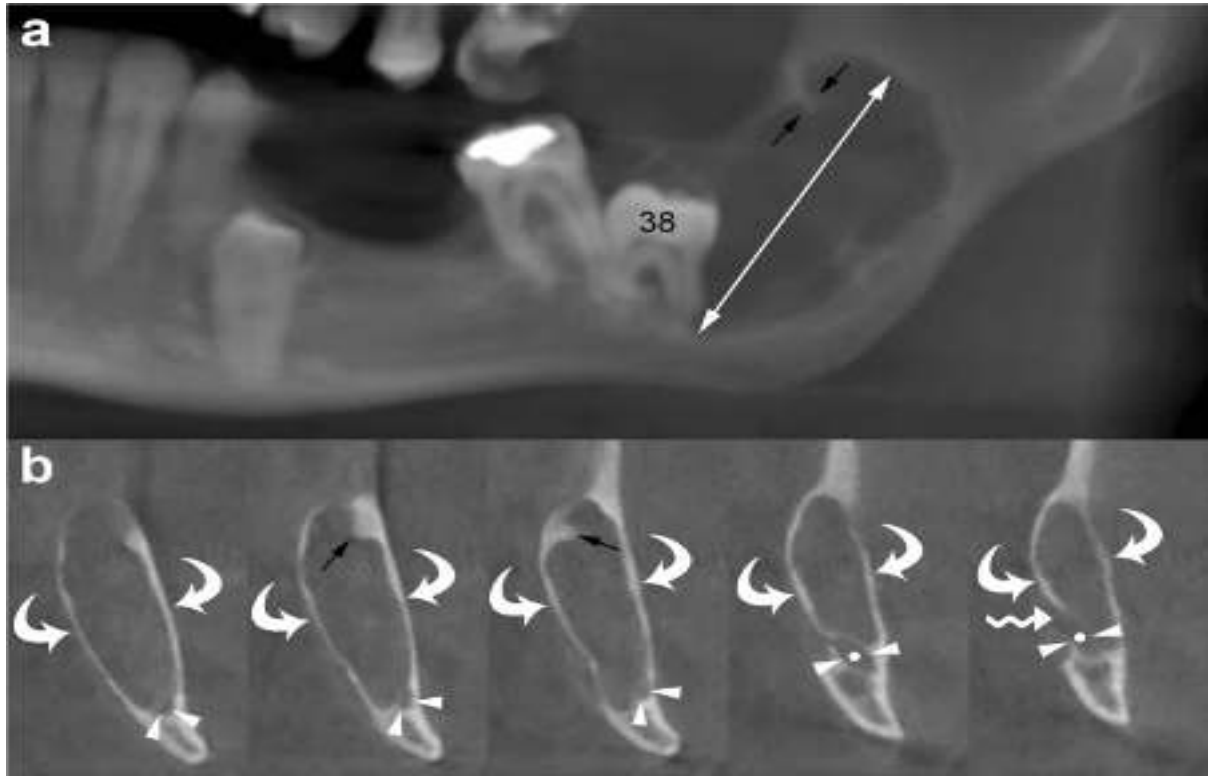

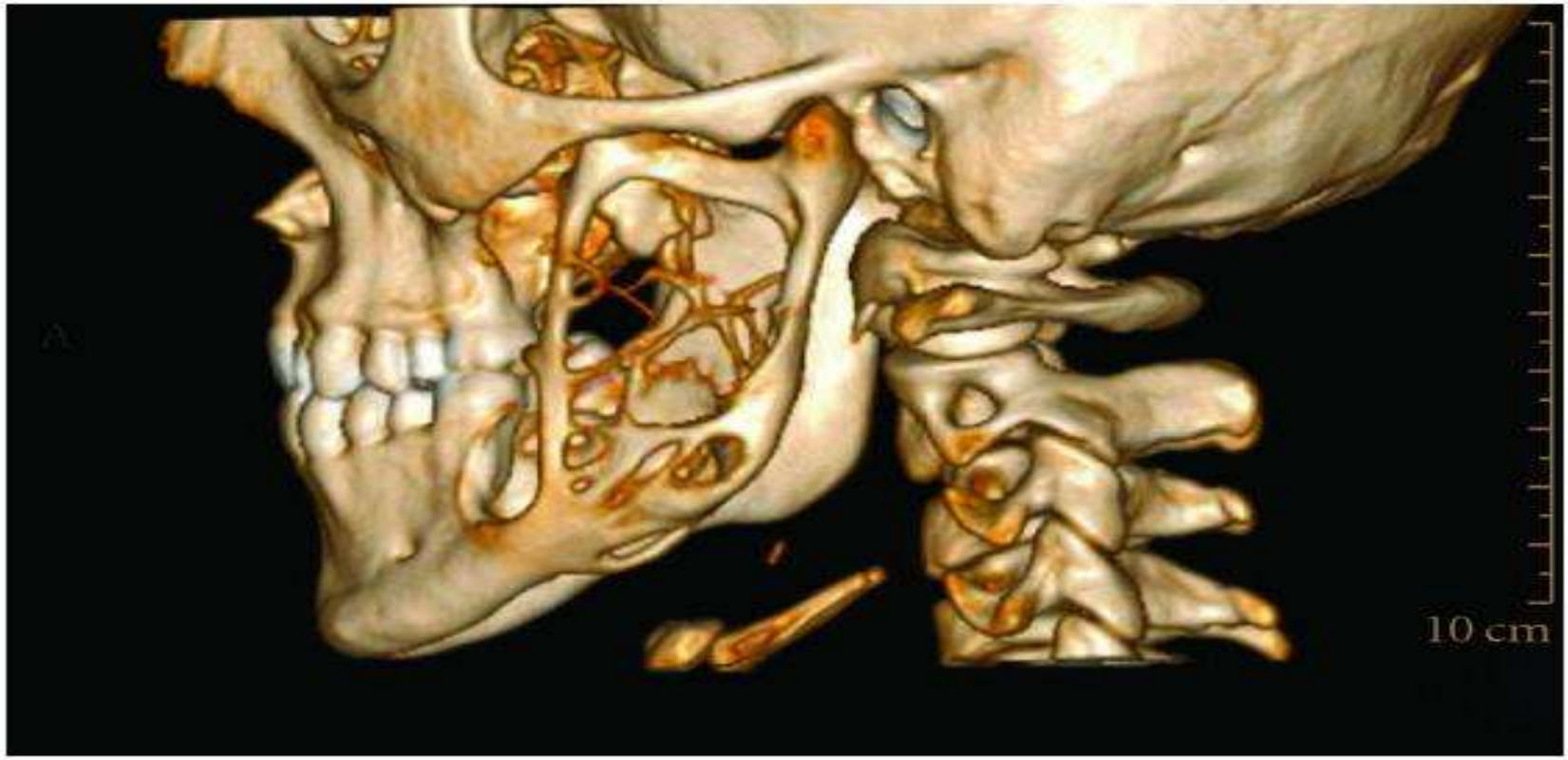

3D CT frontal (a) sagittal (b,c) images demonstrate the lingual, buccal cortical and basis of mandibular erosion with a multilocular bony defect like soup bubble appearance.

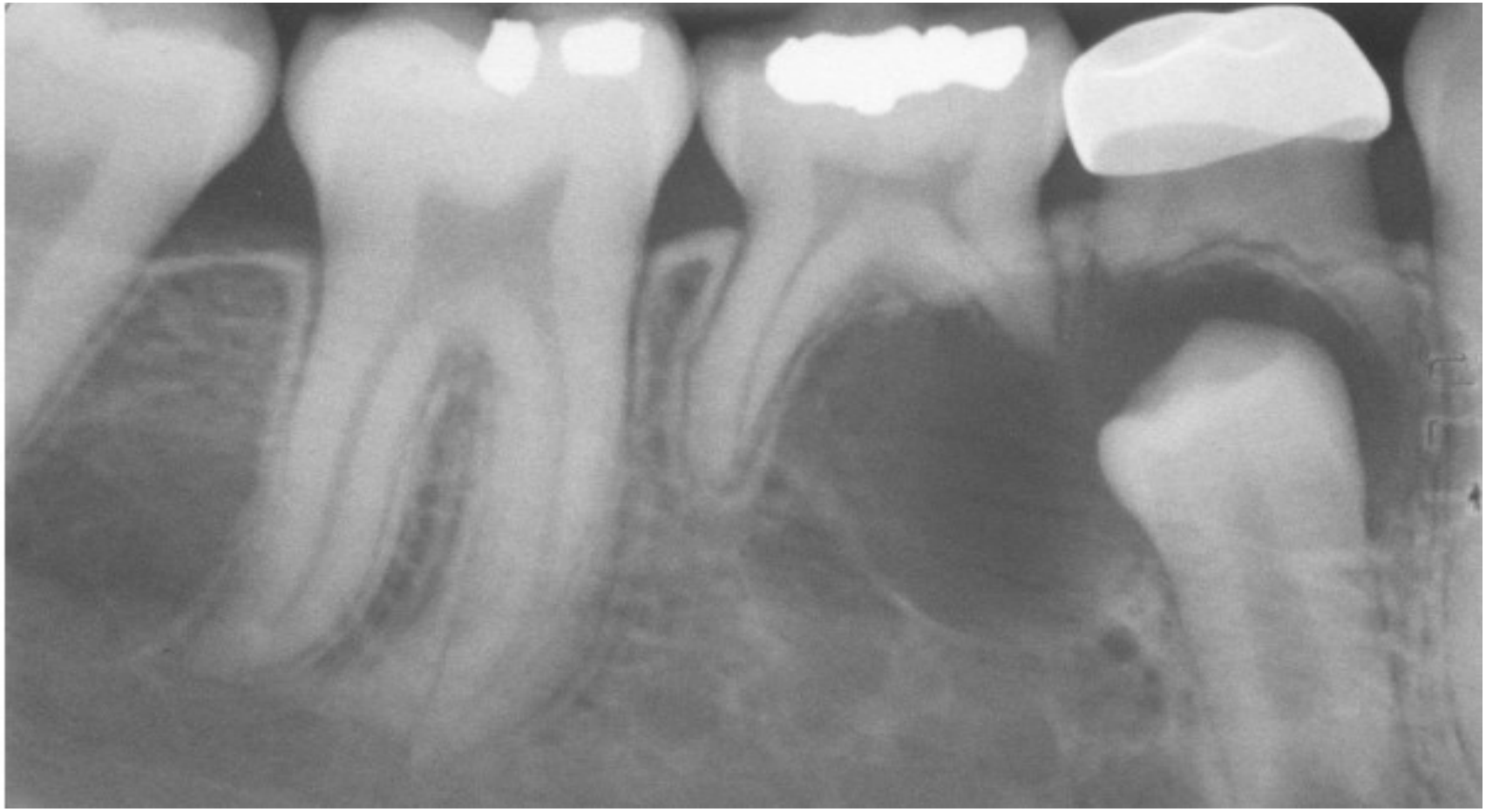

Odontogenic Keratocyst (OKC). **This cyst involves the crown of an unerupted premolar. Radiographically, this lesion cannot be differentiated from a dentigerous cyst.**

Odontogenic Keratocyst (OKC). **Large, multilocular cyst involving most of the ascending ramus.**

Mandibular odontogenic keratocysts (OKCs).

a. OPG shows a unilocular lesion in the posterior mandible and ramus that determines the mesial displacement of the impacted third molar (*curved arrow*).

b. OPG demonstrates a multilocular lesion occupying the posterior mandible and ramus with a soap-bubble pattern

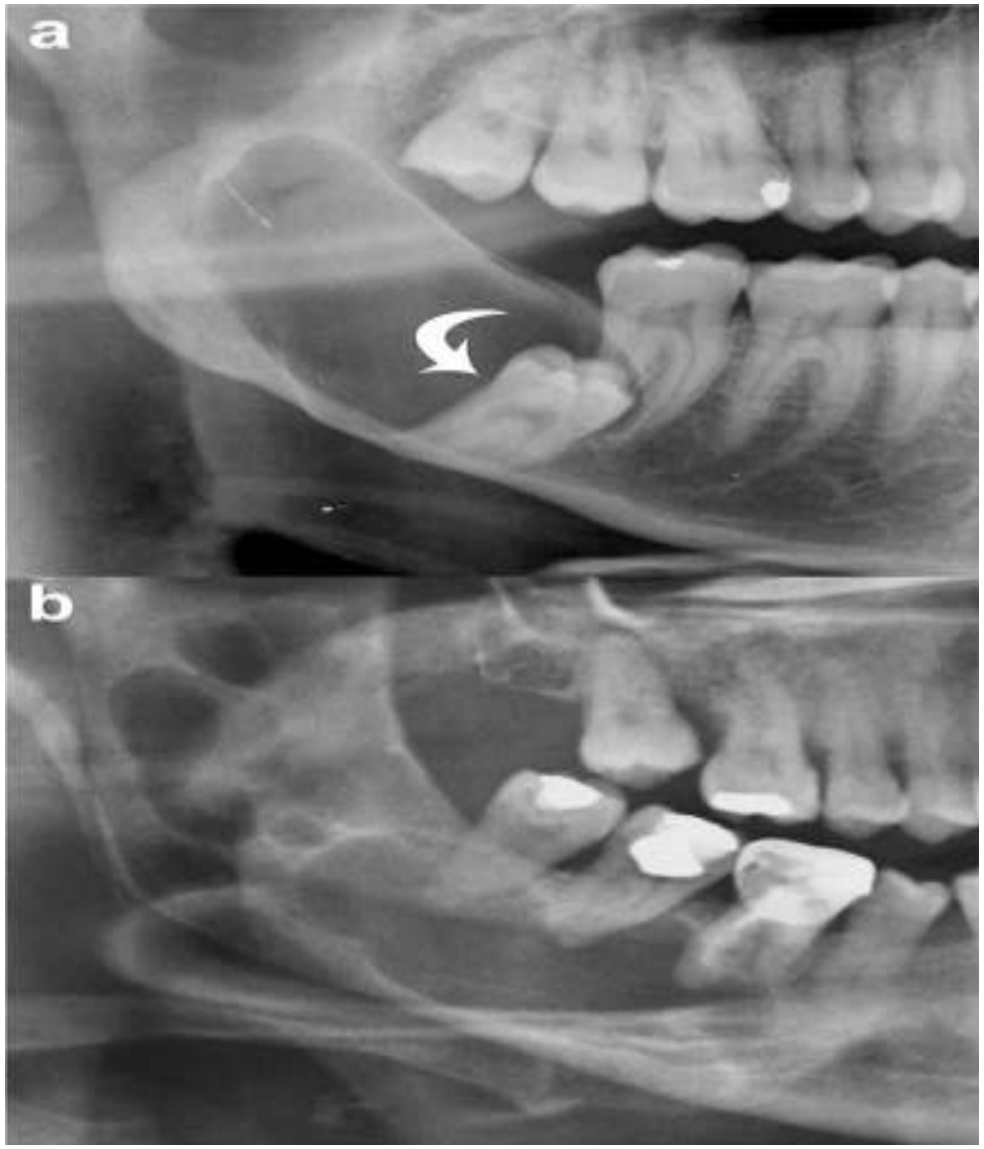

Odontogenic Keratocyst (OKC). **Computed tomography (CT) scan showing a large cyst involving the crown of an unerupted maxillary third molar. The cyst largely fills the maxillary sinus.**

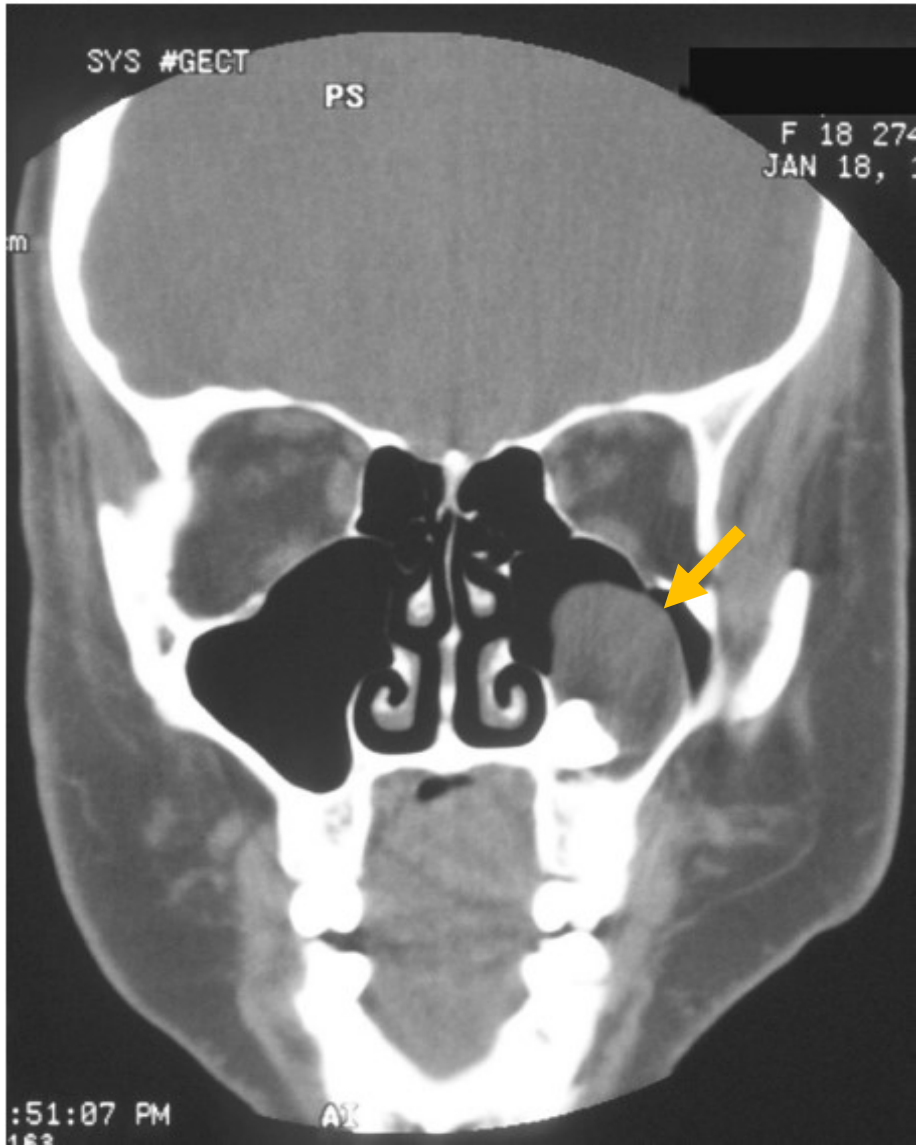

○ **The radiographic findings in an OKC may simulate those of**

- ✓ **dentigerous cyst,**
- ✓ **radicular cyst,**
- ✓ **residual cyst,**
- ✓ **lateraal periodontal cyst,**
- ✓ **globulomaxillary cyst**

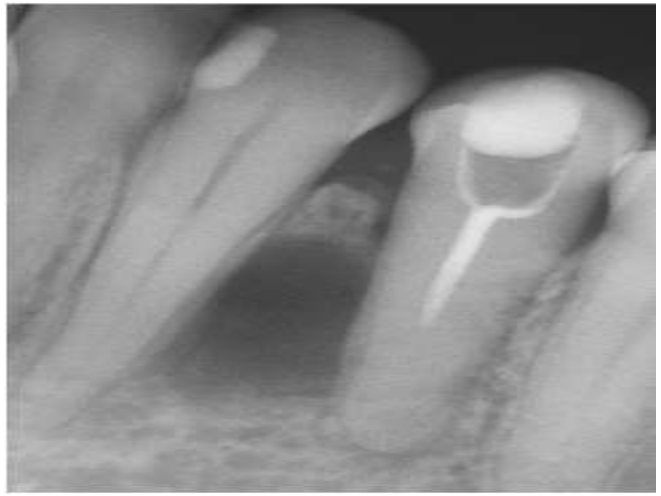

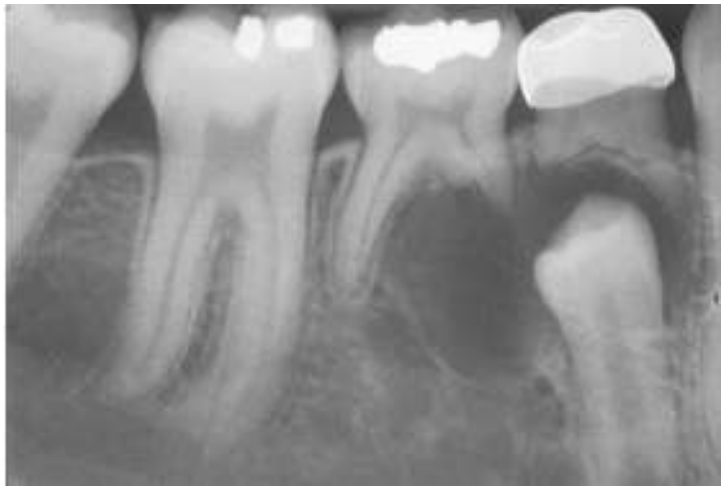

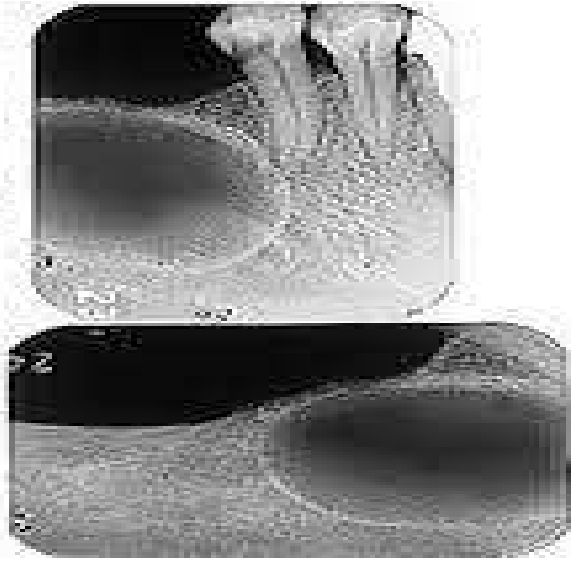

OKCs: conventional radiographs

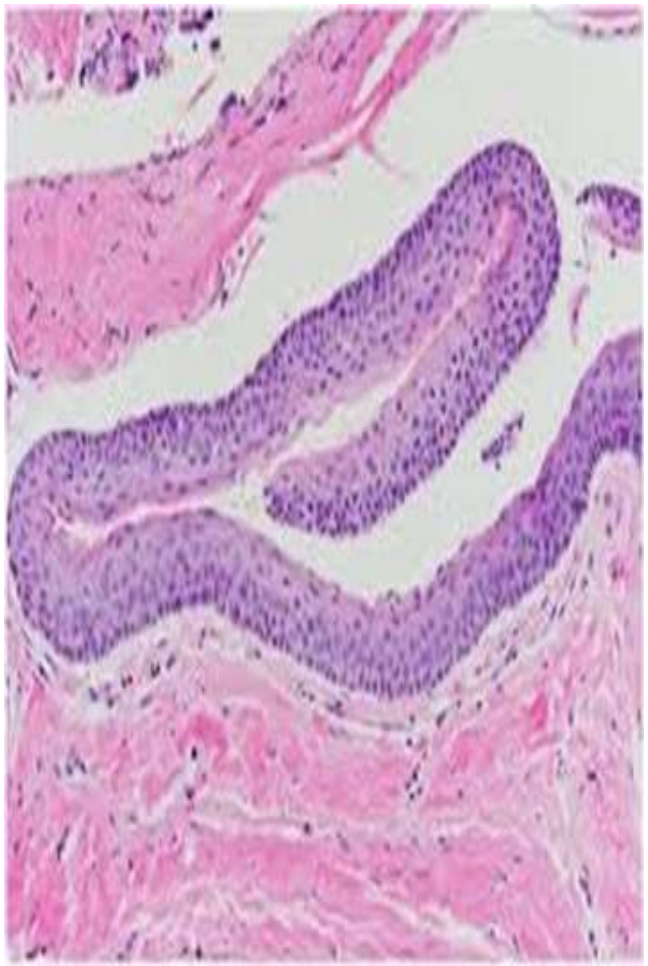

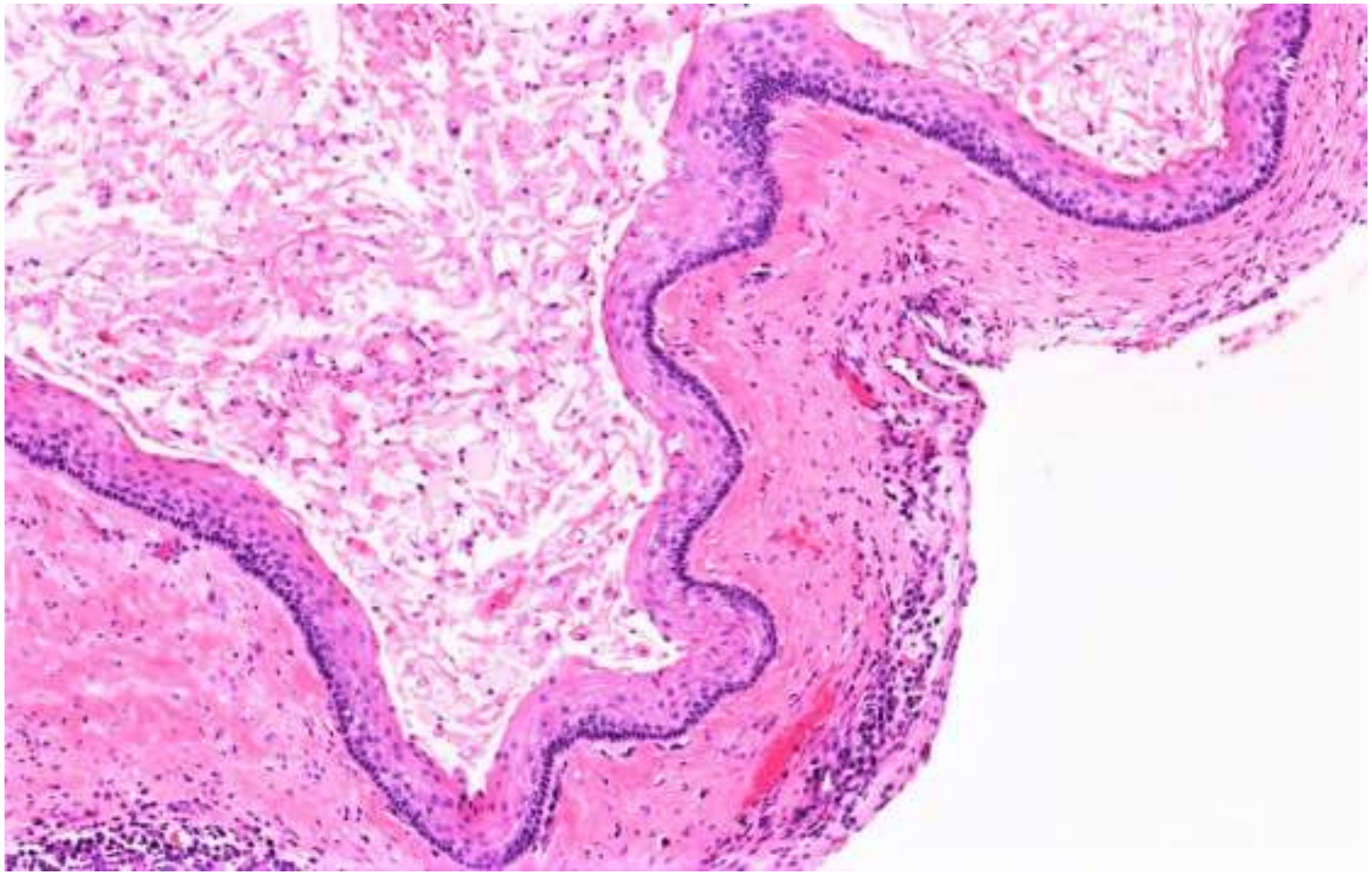

Classic microscopic features of *odontogenic keratocyst*, uniform thickness, absent rete ridges, hyperchromatic basal layer (20x).

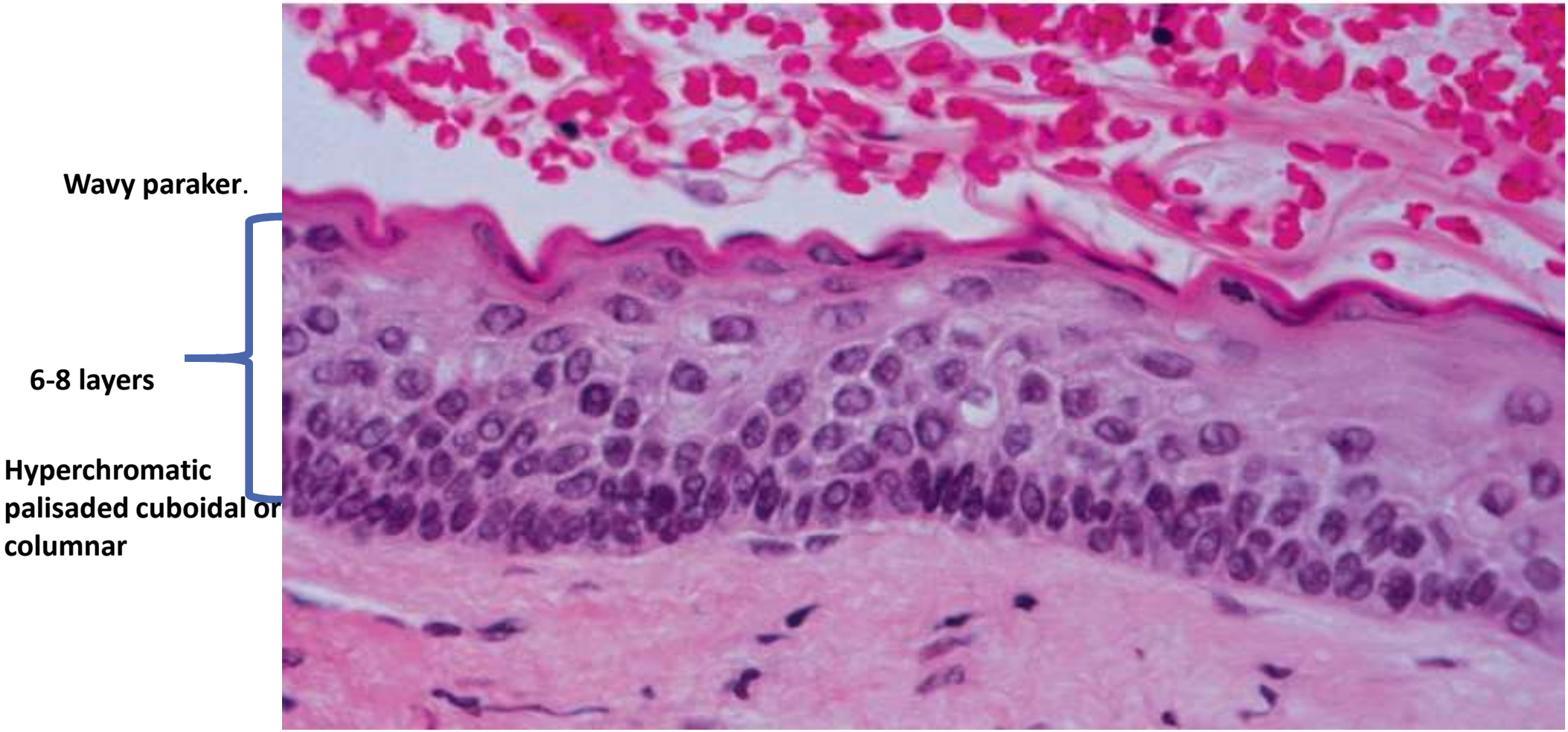

Odontogenic Keratocyst (OKC). **The epithelial lining is 6 to 8 cells thick, with a hyperchromatic and palisaded basal cell layer. Note the corrugated parakeratotic surface.**

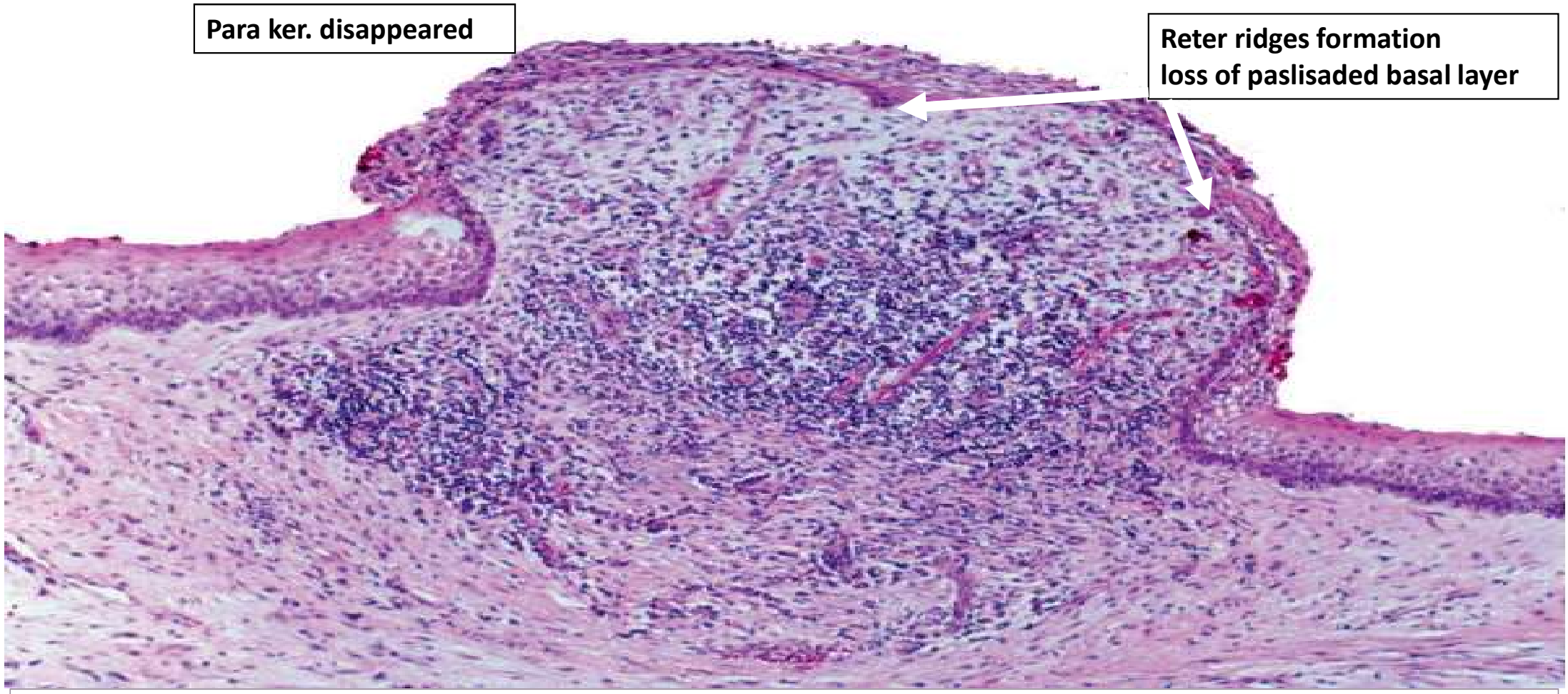

Inflammed OKC. **The characteristic microscopic features have been lost in the central area of this portion of the cystic lining because of the heavy chronic inflammatory cell infiltrate**

Orthokeratinized Odontogenic Cyst

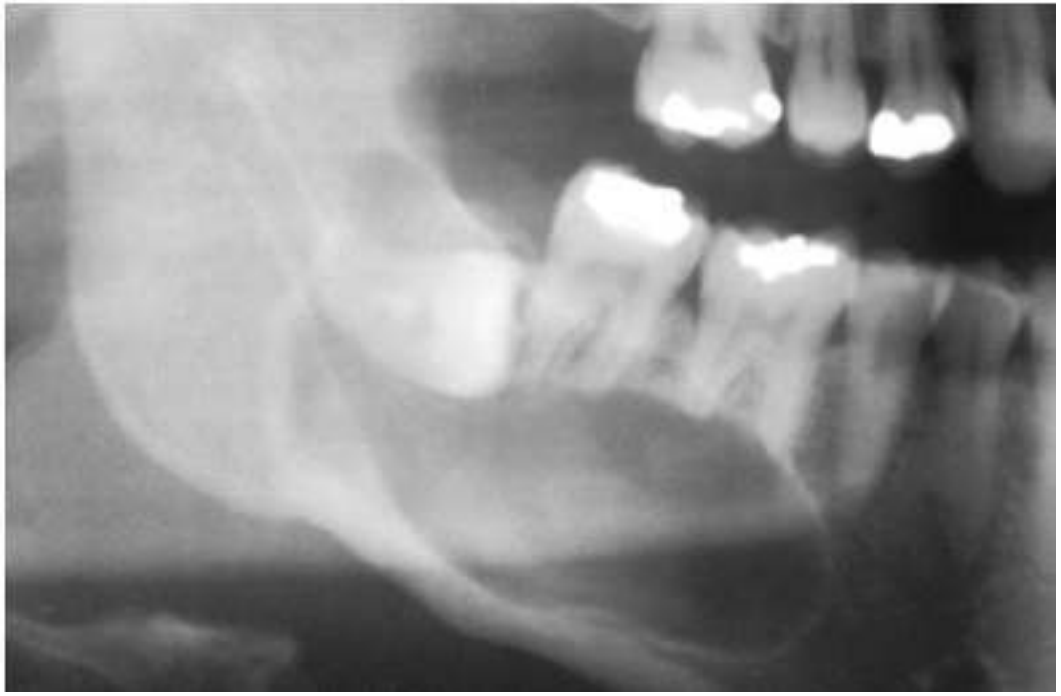

A large cyst involving a horizontally impacted lower third molar

Small unilocular radiolucency associated with the impacted mandibular left third molar

***Orthokeratinized Odontogenic Cyst*. Microscopic features showing a thin epithelial lining. The basal epithelial layer does not demonstrate palisading. Keratohyaline granules are present, and a thick layer of orthokeratin is seen on the luminal surface.**

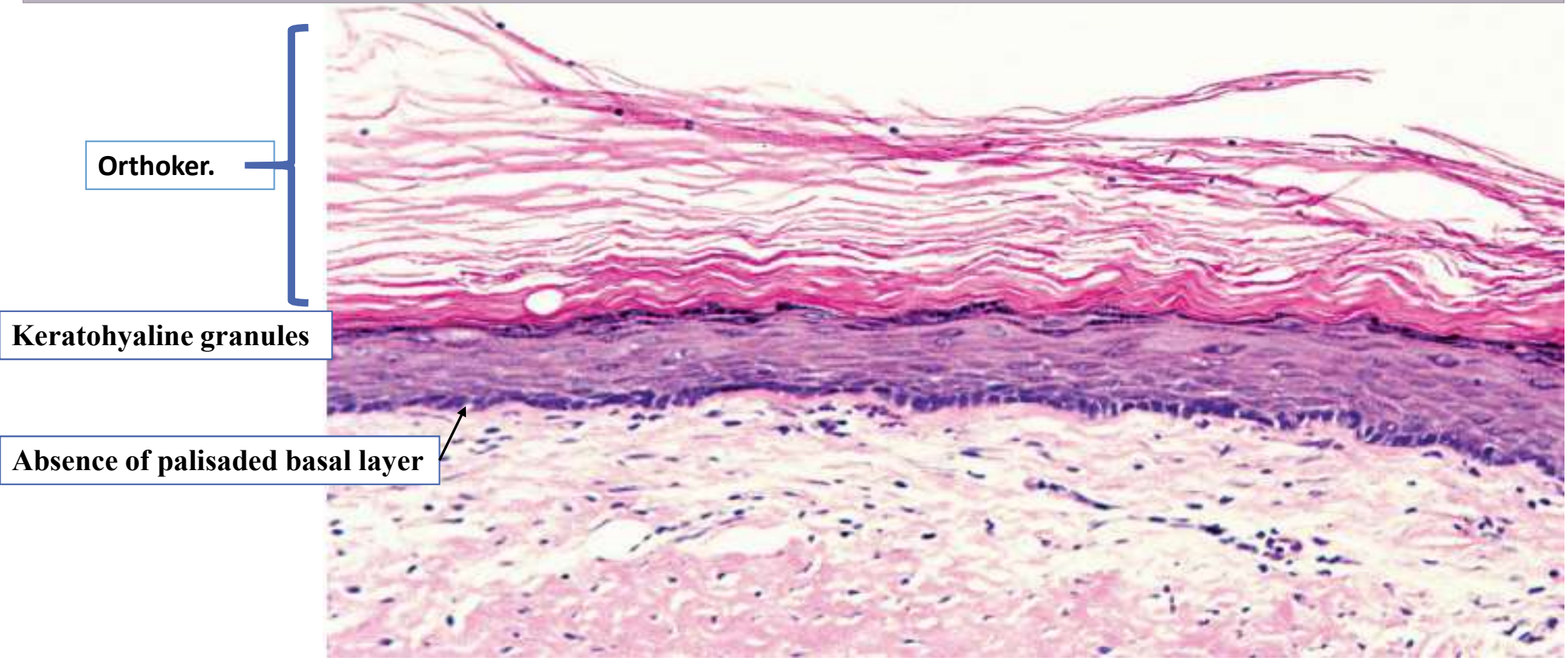

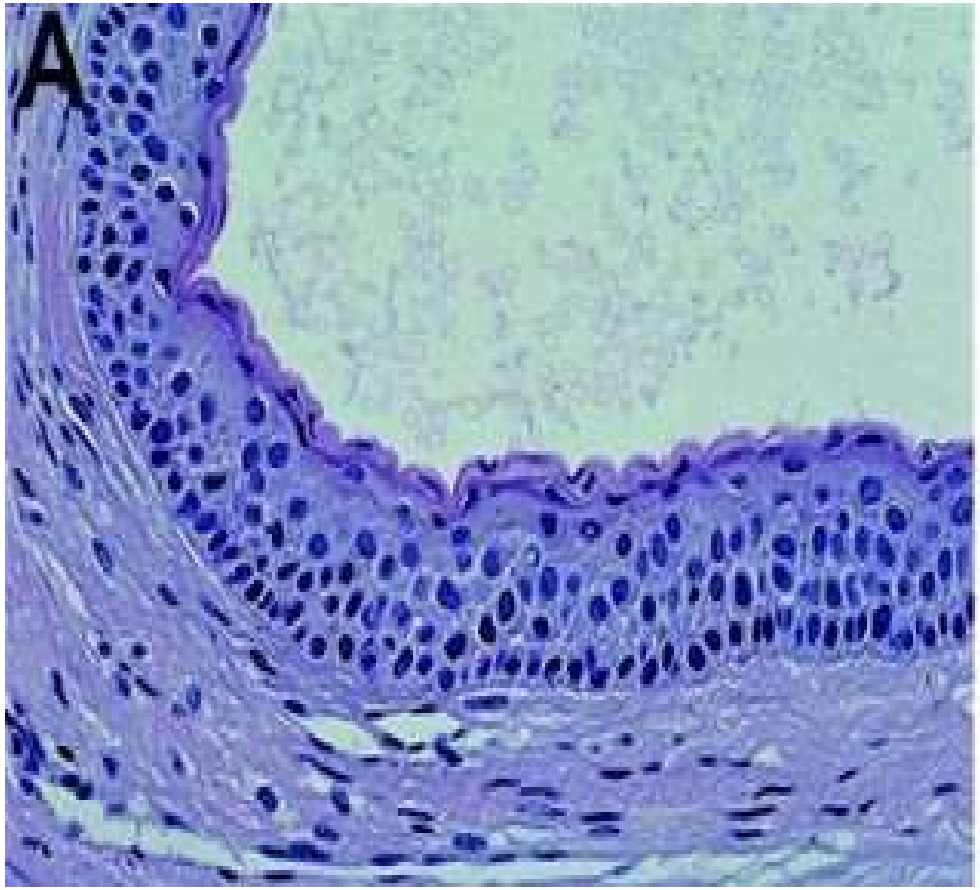

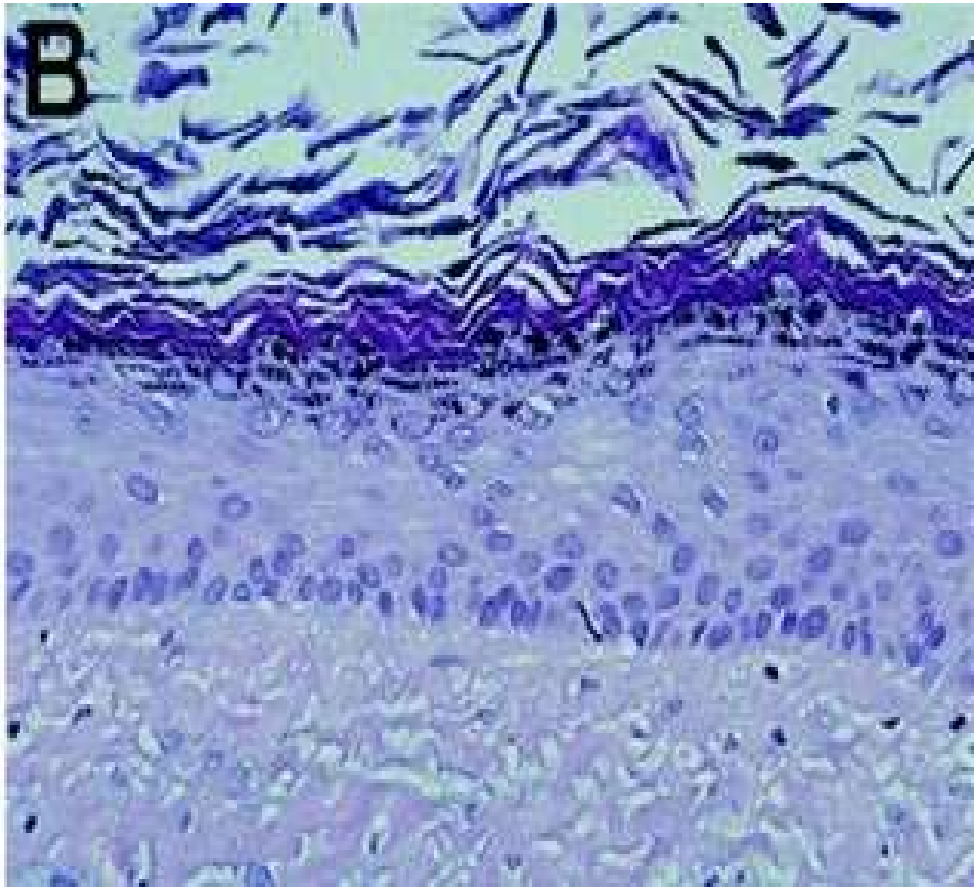

OKC

Orthokeratinized odontogenic cyst

Treatment and Prognosis

- *Enucleation with curettage*

Odontogenic keratocyst	Orthokeratinized odontogenic cyst
Relatively high recurrence rate (30%)	Low recurrence rate(2%)
Malignant transformation high	Malignant transformation scant
Associated with Gorlin syndrom	Not associated with Gorlin syndrom

- Is an uncommon, occurs along the lateral root surface of a tooth.
- Arise from *rests of the dental lamina*.
- In the past, the term lateral periodontal cyst was used to describe any cyst that developed along the lateral root surface, including lateral radicular cysts and OKCs. However, the lateral periodontal cyst has distinctive clinical and microscopic features that distinguish it from other lesions that sometimes develop in the same location

Lateral Periodontal Cyst. A larger lesion causing root divergence

Lateral Periodontal Cyst. Radiolucent lesion between the roots of a vital mandibular canine and first premolar

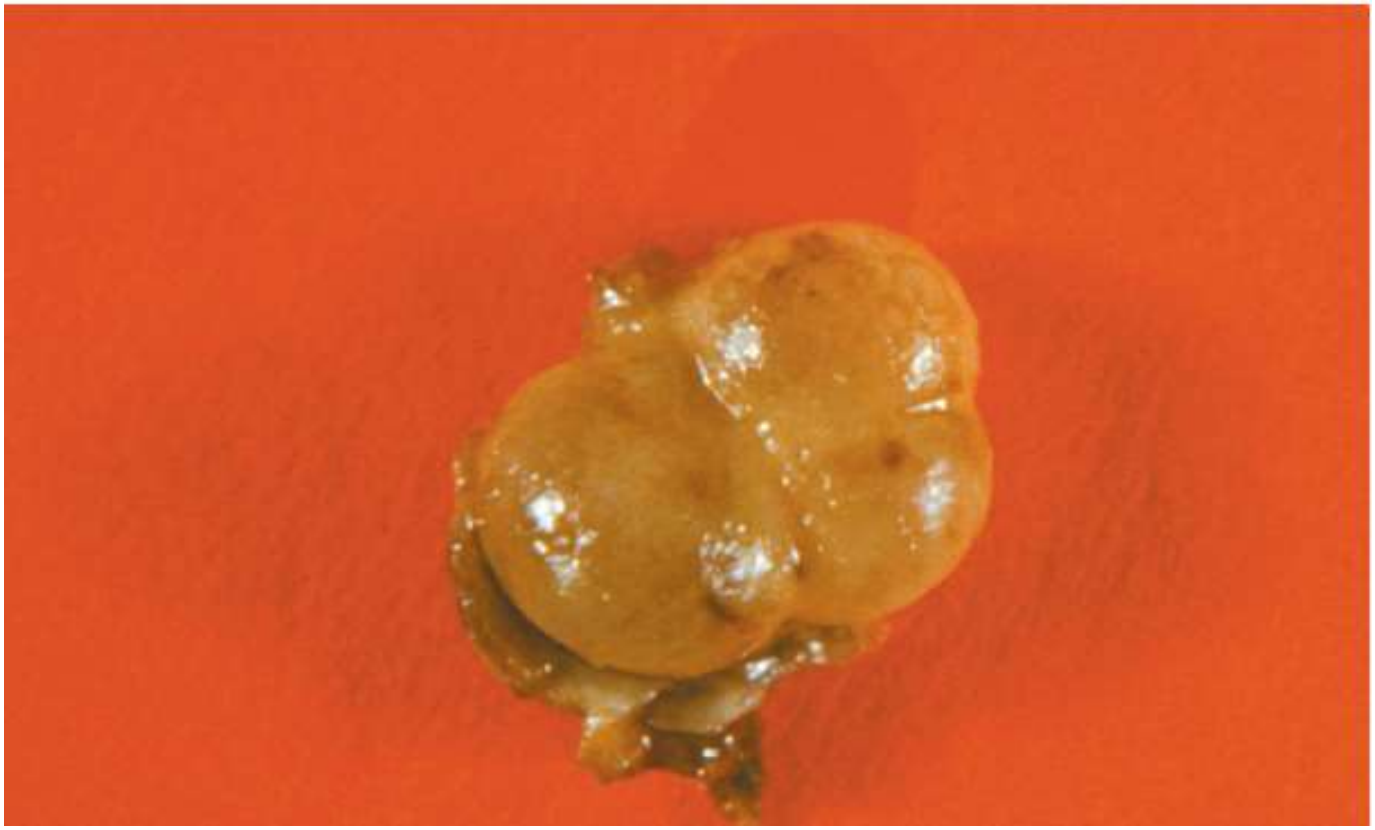

***Lateral Periodontal Cyst*. Gross specimen of a botryoid variant. Microscopically, this grapelike cluster revealed three separate cavities.**

Lateral Periodontal Cyst.

A, This photomicrograph shows a thin epithelial lining with focal nodular thickenings(star).

B, These thickenings often show a swirling appearance of the cells

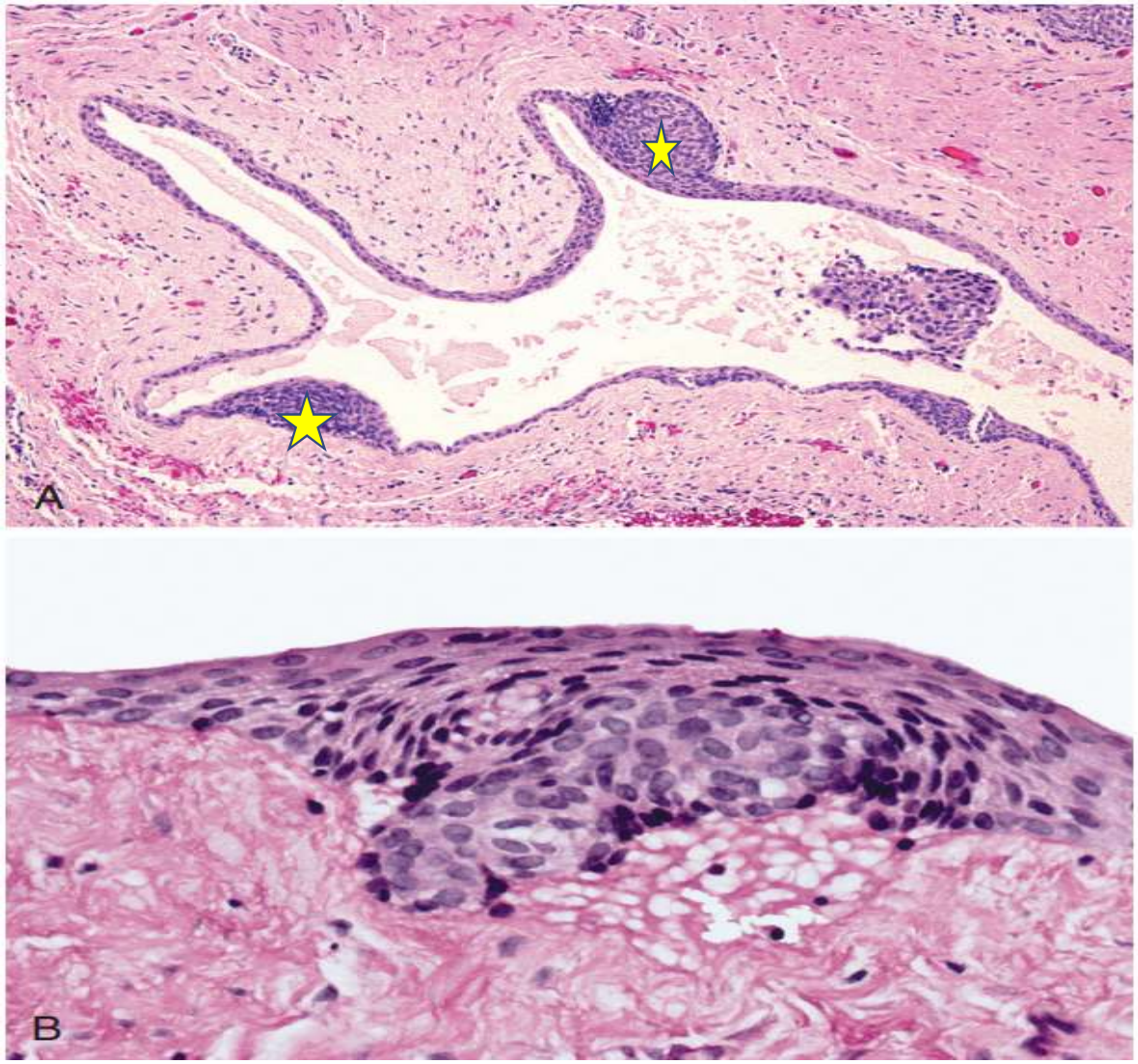

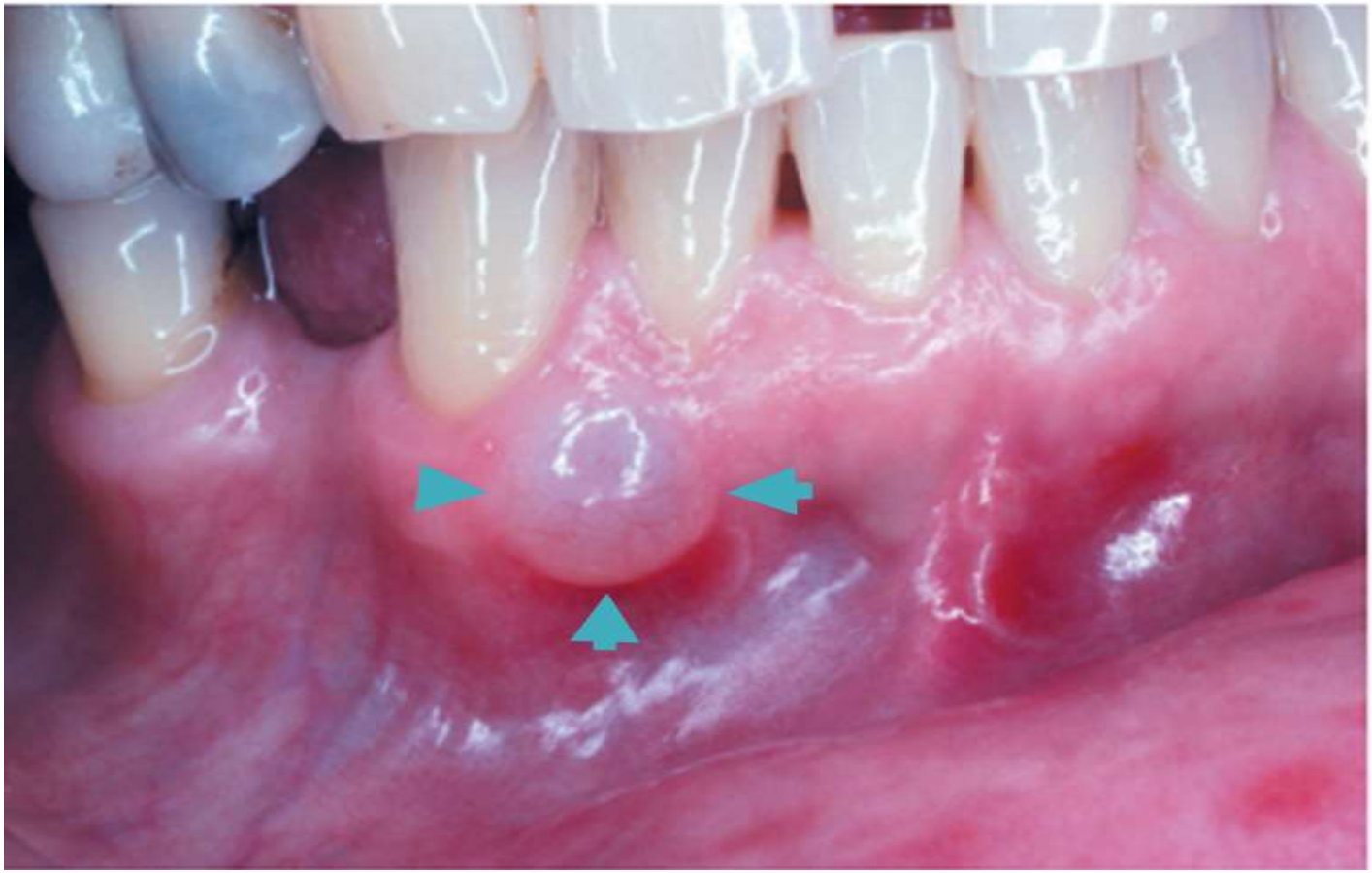

***Gingival Cyst of the Adult*. Tense, fluid-filled swelling on the facial gingiva.**

***Gingival Cyst of the Adult*. Low-power photomicrograph showing a thin-walled cyst in the gingival soft tissue.**

8◆ CALCIFYING ODONTOGENIC CYST (COC)

- ✓ It is part of a spectrum of lesions characterized by odontogenic epithelium containing "ghost cells," which then may undergo calcification.
- ✓ most examples grow in a cystic fashion, some occur as solid tumor-like growths (dentinogenic ghost cell tumor).
- ✓ Therefore, in the current WHO classification system, these lesions have been categorized as ***odontogenic tumors*** under three categories (based on the cystic, solid, or malignant nature of the lesion):

    1. *Calcifying cystic odontogenic tumor*
    2. *Dentinogenic ghost cell tumor*
    3. *Ghost cell odontogenic carcinoma*

A-Intraosseous(central) calcifying odontogenic cysts(COC)

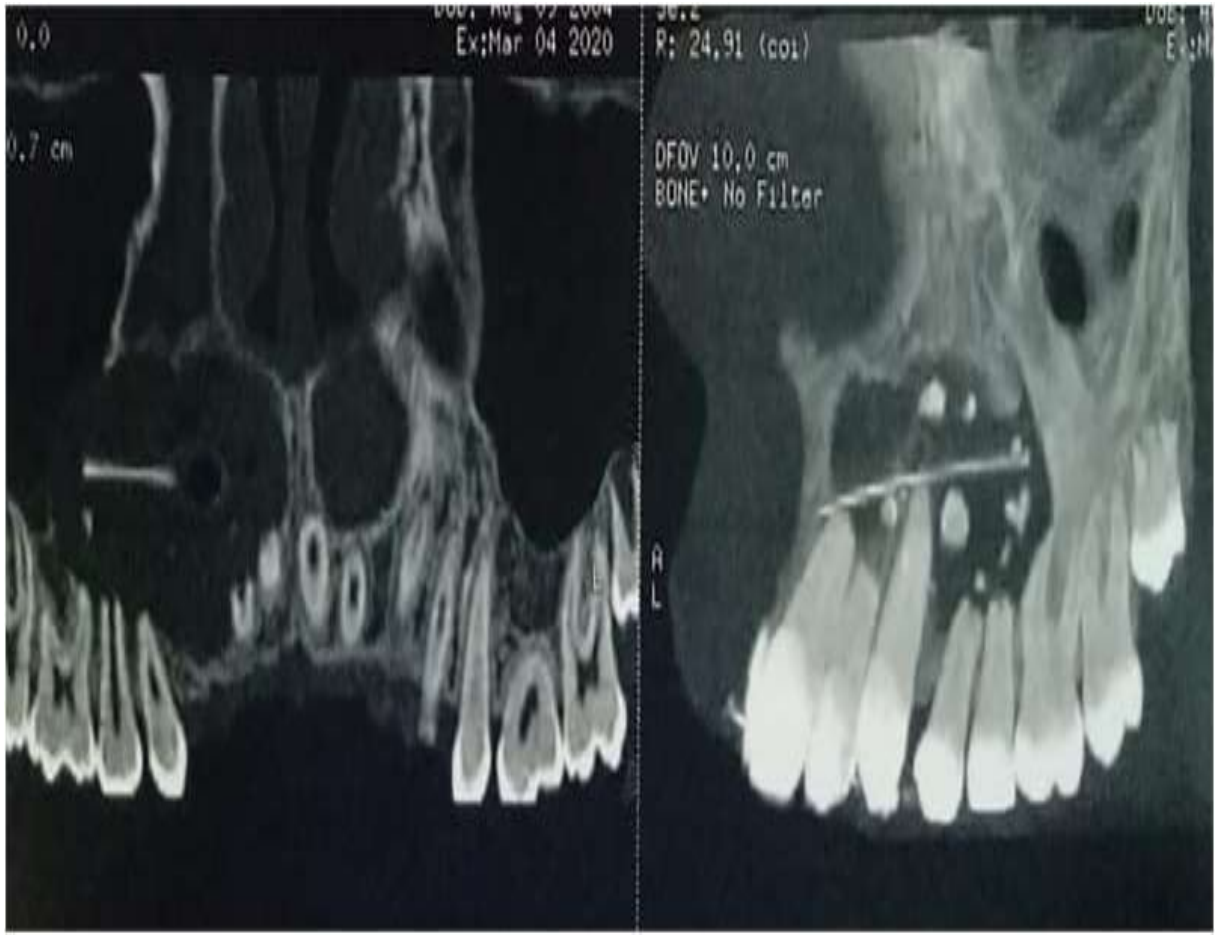

Calcifying odontogenic cyst

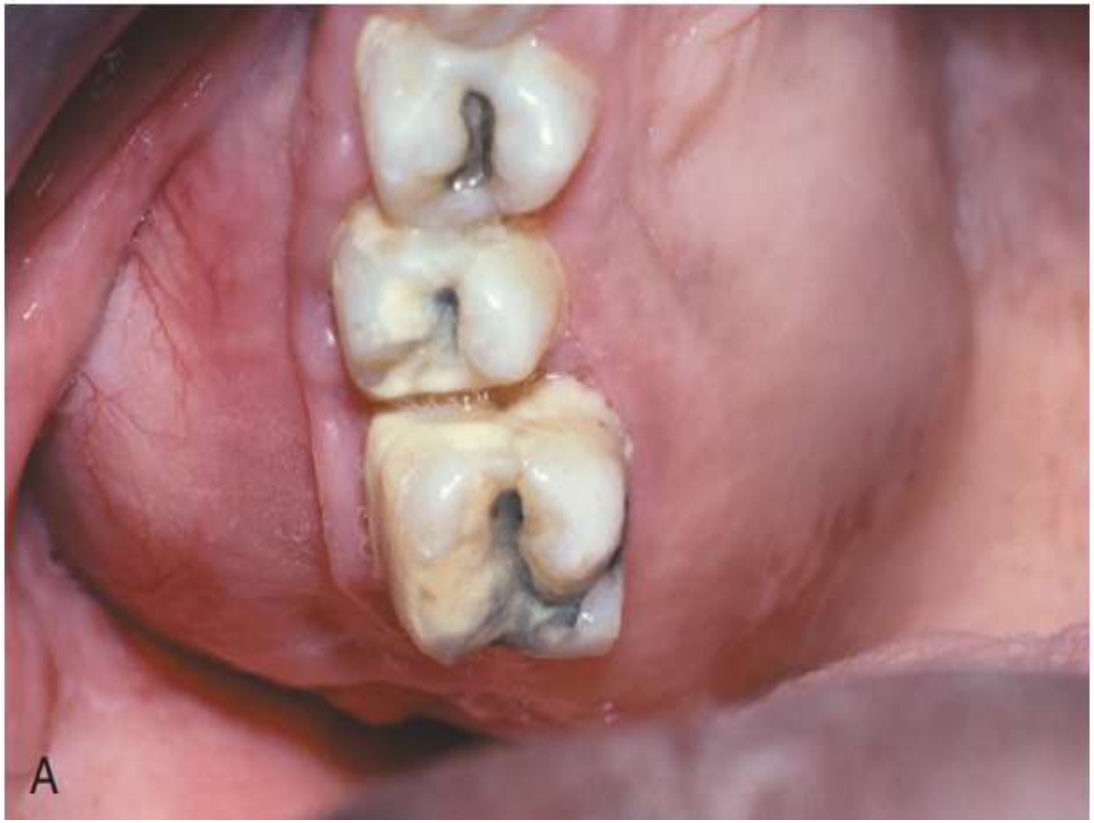

Calcifying Odontogenic Cyst.

A, Expansion of the posterior maxillary alveolus caused by a large calcifying odontogenic cyst.

B, Panoramic radiograph of the same patient showing a large radiolucency in the posterior maxilla. A small calcified structure is seen in the lower portion of the cyst.

Peripheral Calcifying Odontogenic Cyst. Nodular mass of the mandibular facial gingiva.

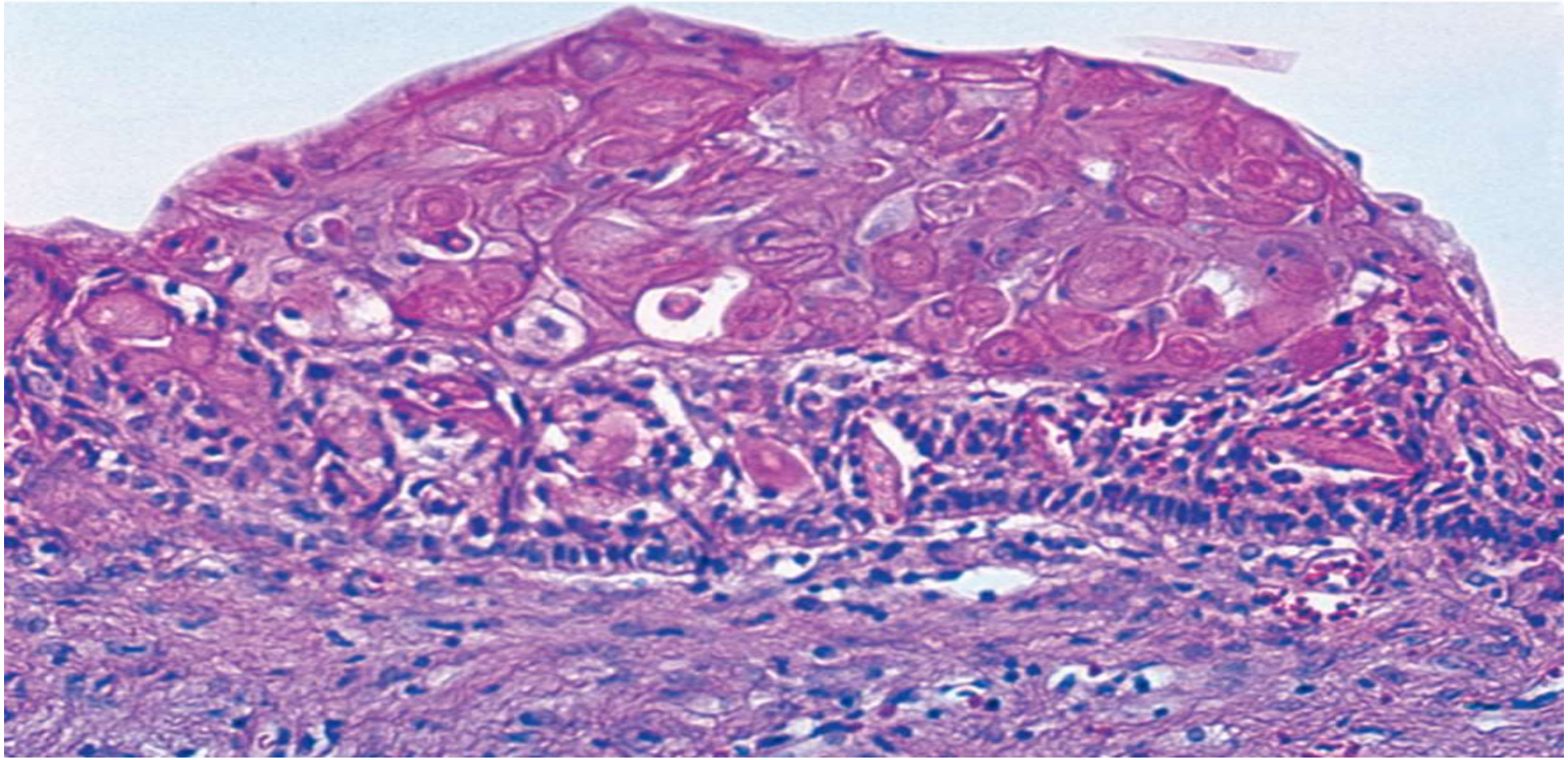

***Calcifying Odontogenic Cyst*. The cyst lining shows ameloblastoma-like epithelial cells, with a columnar basal layer. Large eosinophilic ghost cells are present within the epithelial lining.**

Calcifying Odontogenic Cyst.
Eosinophilic dentinoid material is present adjacent to a sheet of ghost cells(star).

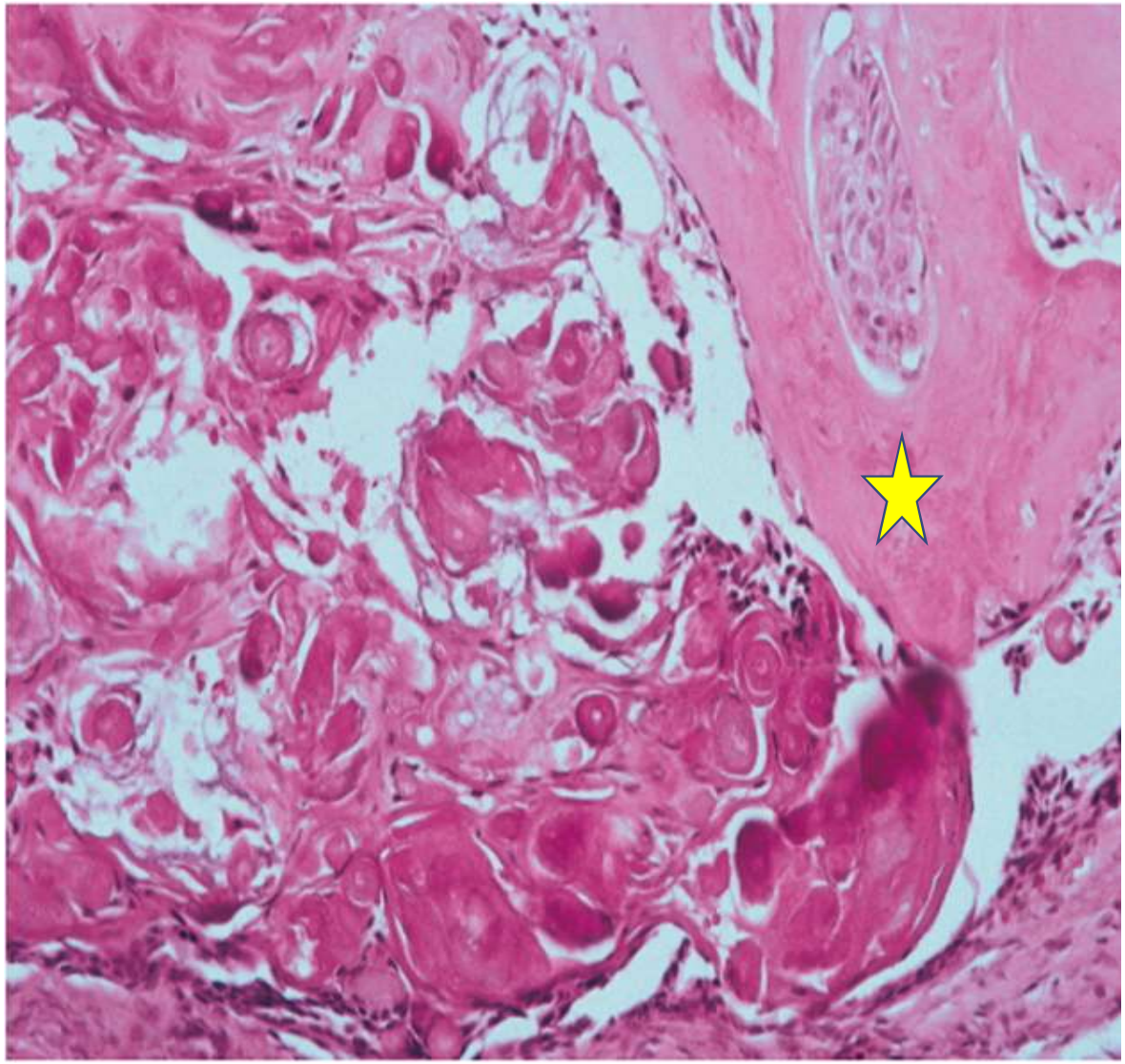

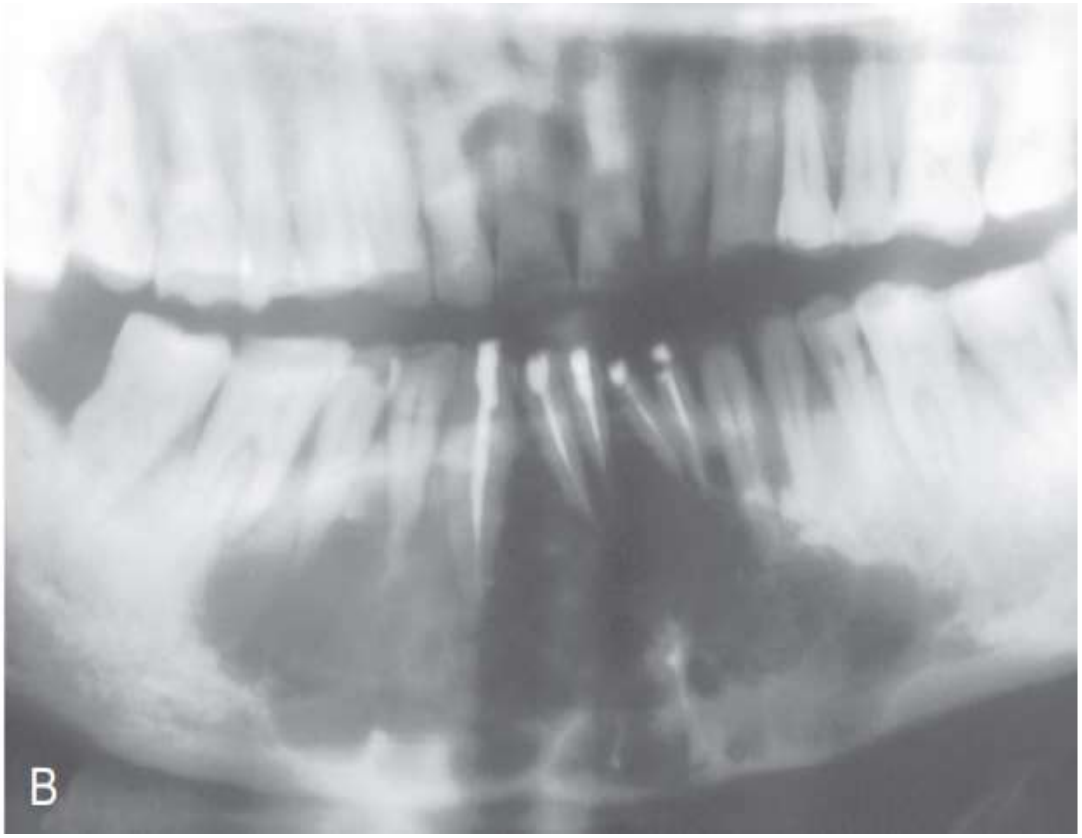

Glandular Odontogenic Cyst.

A, Expansile lesion of the anterior mandible.

B, The panoramic radiograph shows a large multilocular radiolucency

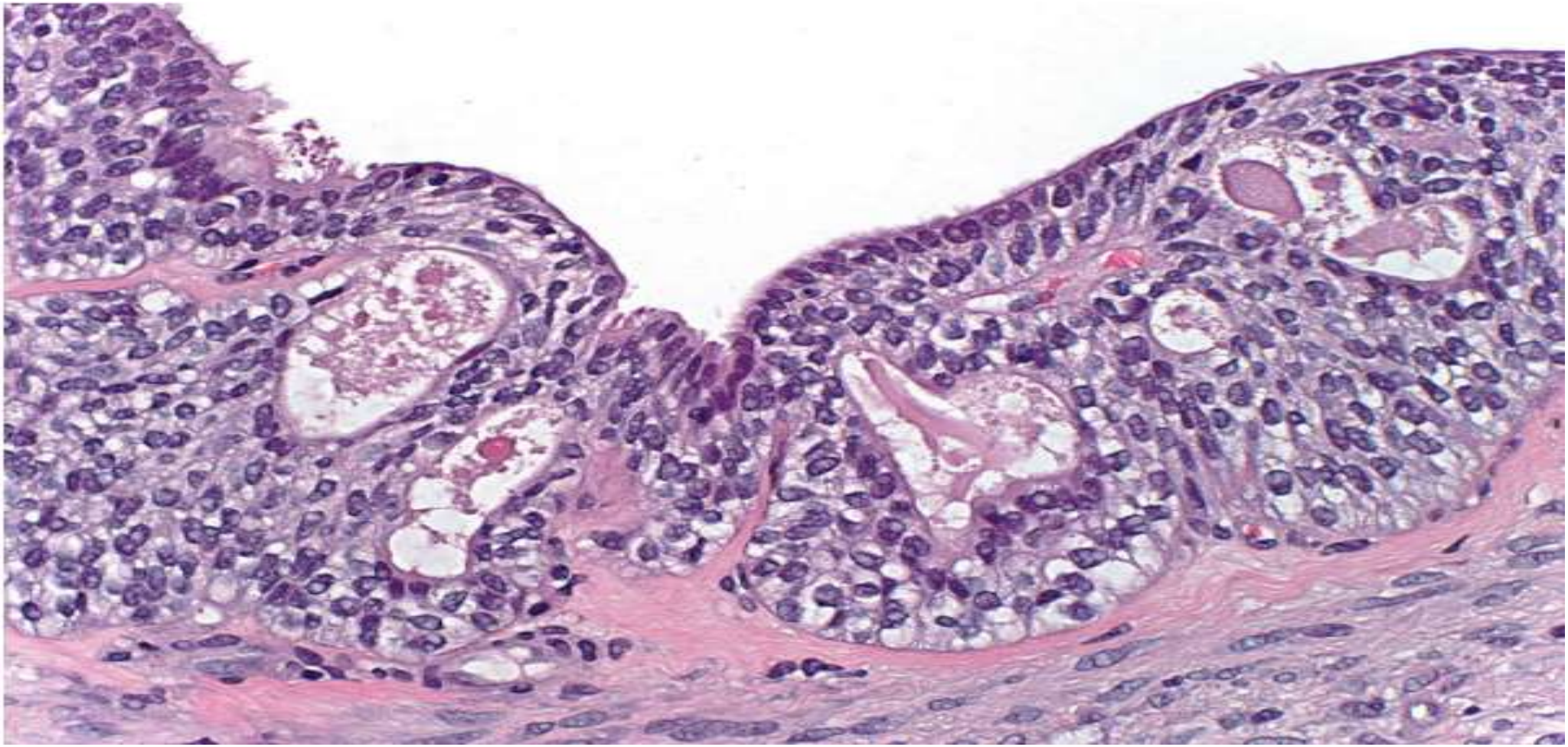

Glandular Odontogenic Cyst. **The cyst is lined by stratified squamous epithelium that exhibits surface columnar cells with cilia. Numerous microcysts containing mucinous material are present.**

Thank you